HYPERMOBILITY SYNDROME: FINDINGS ON A UNDERESTIMATED DIAGNOSIS OF CARPAL INSTABILITY NONDISSOCIATIVE BY THE RADIOLOGIST

André Henrique Nogueira de Toledo
Jhulia Gabriela Duarte de Sousa
Thaisa Lazari Gomes
Daniel Miranda Ferreira
Eduardo Jose Mariotoni Bronzatto
Sérgio San juan Dertkgil

SUBSPECIALTY : Musculoskeletal Imaging
TYPE OF ABSTRACT : Education Exhibit

UNICAMP

RCC Radiologia Clínica de Campinas

Department of Radiology, State University of Campinas (Unicamp), Brazil

José Michel Kalaf Research Institute, Campinas, Brazil

The authors have no conflict of interest to disclosure in this presentation

INTRODUCTION

Carpal instability is a complex and heterogeneous clinical condition. Management requires accurate identification of the structural lesion involved.

Carpal Instability Dissociative (CID) demonstrate derangement within or between bones of the same carpal row.

Carpal Instability non-dissociative (CIND) can be caused by various combinations of intrinsic and extrinsic ligament injuries with abnormal kinematics between the carpal rows.

Joint hypermobility occurs due to connective tissue laxity and is clinically characterized by chronic joint pain due to instabilities caused by ligament injuries. It may be caused by **Inherited connective tissue disorders** (Marfan, osteogenesis imperfecta), **benign hypermobility syndrome (**spectrum disorders related to Ehlers-Danlos or Hypermobility Type), and **secondary** (trauma, neurological, muscle diseases...).

Such instability is related to biomechanical alterations of multiple causes that, **if not identified and treated in a timely manner, will lead to gradual joint collapse.**

OBJECTIVES

Review the anatomical structures of the wrist;

How to make the correct diagnosis and classification of the instability;

Detect initial findings of joint hypermobility Magnetic Resonance Imaging (MRI);

Search for complications and joint sequelae, which the radiologist must be aware of;

Discuss joint hypermobility differential diagnoses.

WHICH FINDINGS SHOULD YOU EXPECT?
WHAT DIFFERENTIAL DIAGNOSIS WOULD YOU THINK?

Female, 7 years old, wrist arthralgia, worse on the left. She shows apparent wrist deformity - dorsal deviation of the ulna and volar carpus (picture). Refers to previous episodes of arthralgia in other joints (shoulders and ankles), with complete resolution of the condition. No trauma history. Mother had previous wrist surgery to correct Madelung's deformity and refers to the current diagnosis of Ehlers Danlos syndrome. - Medical request: “Suspicion of Madelung”.

A common presentation during anamnesis

HIGHTLIGHTS OF THE CARPAL ANATOMY

RIGHT HAND - PALMAR VIEW

Scaphoid
Lunate
Triquetrum
Pisiform
Trapezium
*trapezium tubercule
Trapezoid
Capitate
Hamate
* Hook of hamate

RIGHT HAND - DORSAL VIEW

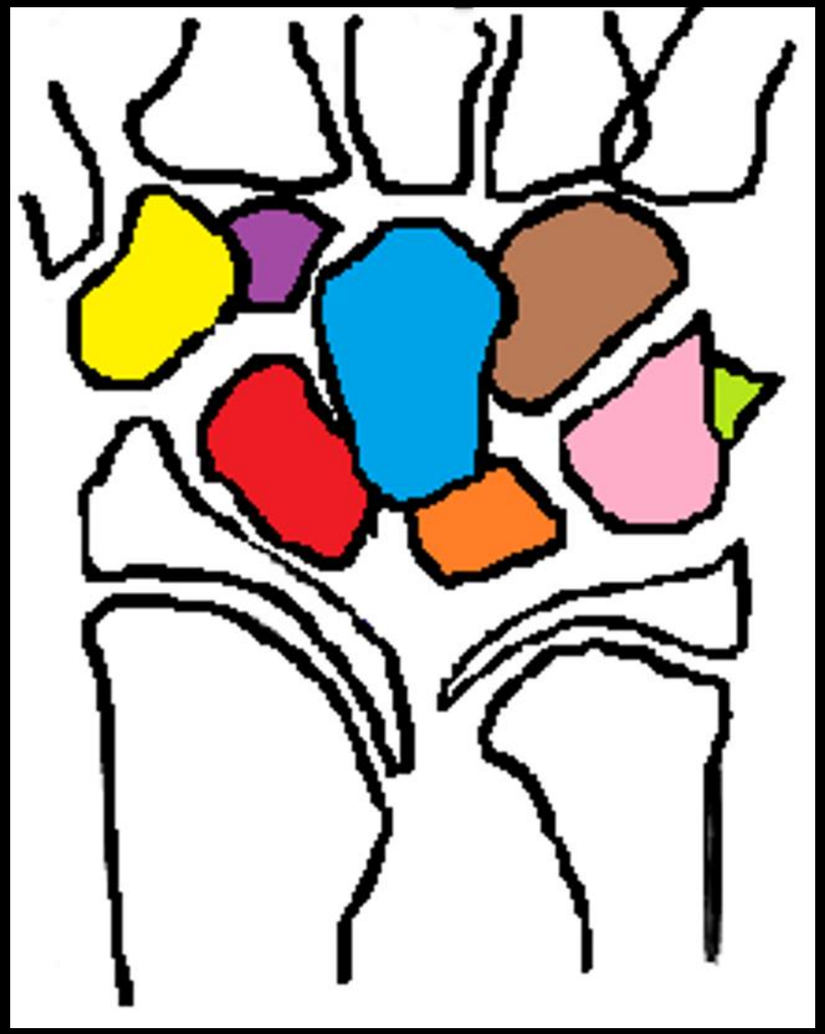

HIGHTLIGHTS OF THE CARPAL ANATOMY

RIGHT HAND - PALMAR VIEW

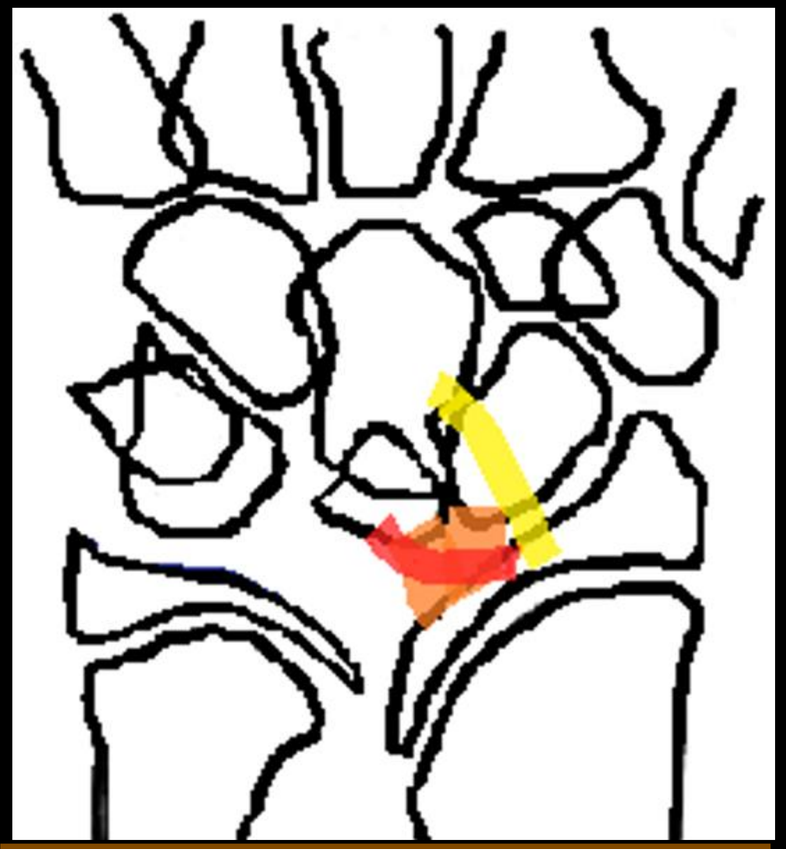

Extrinsic ligaments (main):

- radioscaphoid (yellow)
- radiolunotriquetral (orange)
- radiolunate (red)

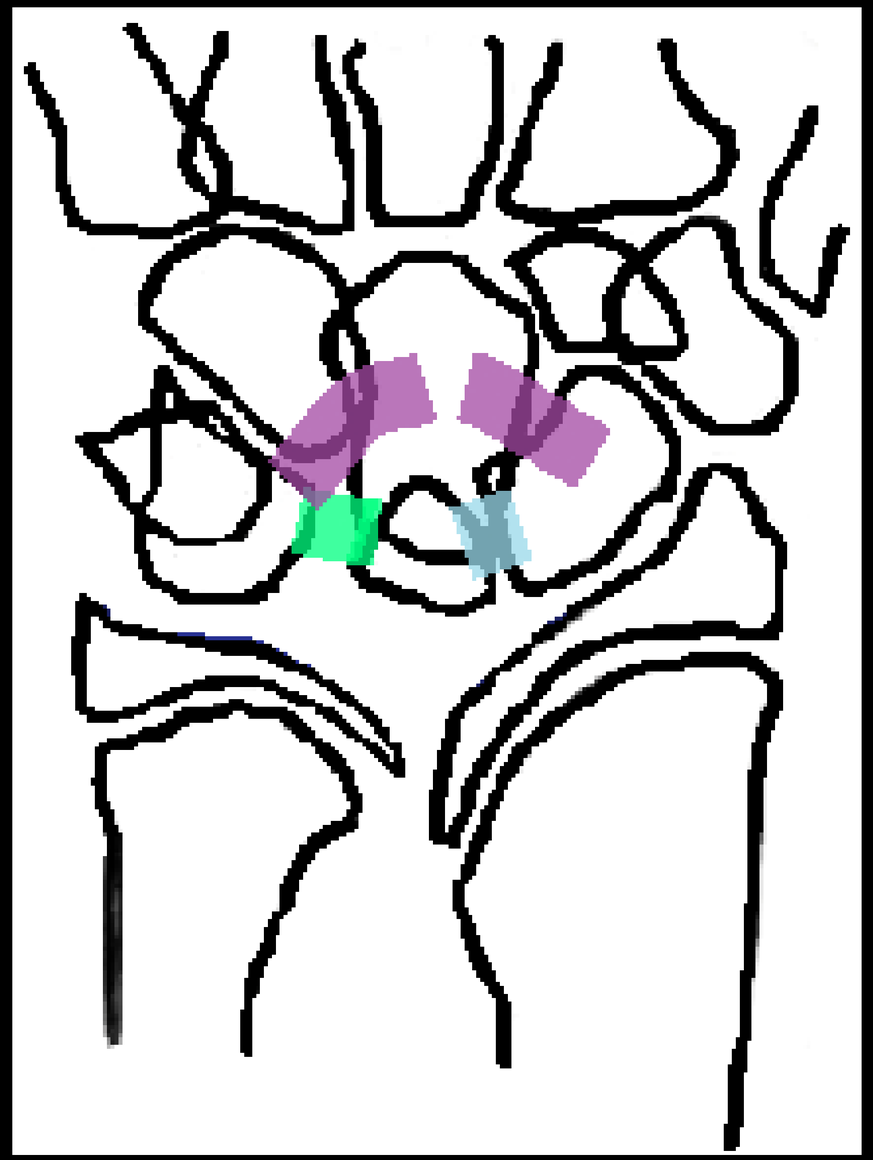

Intrinsic ligaments (main):

- Scapholunate (blue). ★ DISI (dorsal, intermediate and volar component)
- Lunotriquetal (green) ★ VISI (dorsal, proximal and volar component)
- Arcuate ligament of the wrist (1) the ulnar arm, with its attachments to the triquetrum and capitate, with fibers that course over the palmar body of the hamate. VISI ★ (2) the radial arm (SC ligament) with its attachments to the scaphoid and capitate

HIGHTLIGHTS OF THE CARPAL ANATOMY

RIGH HAND - DORSAL VIEW

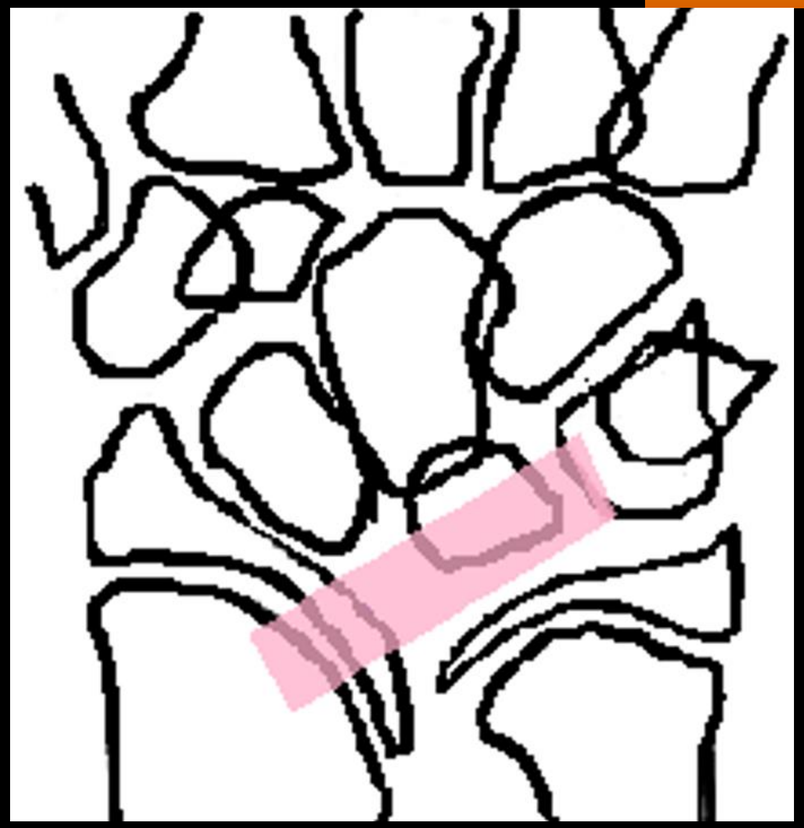

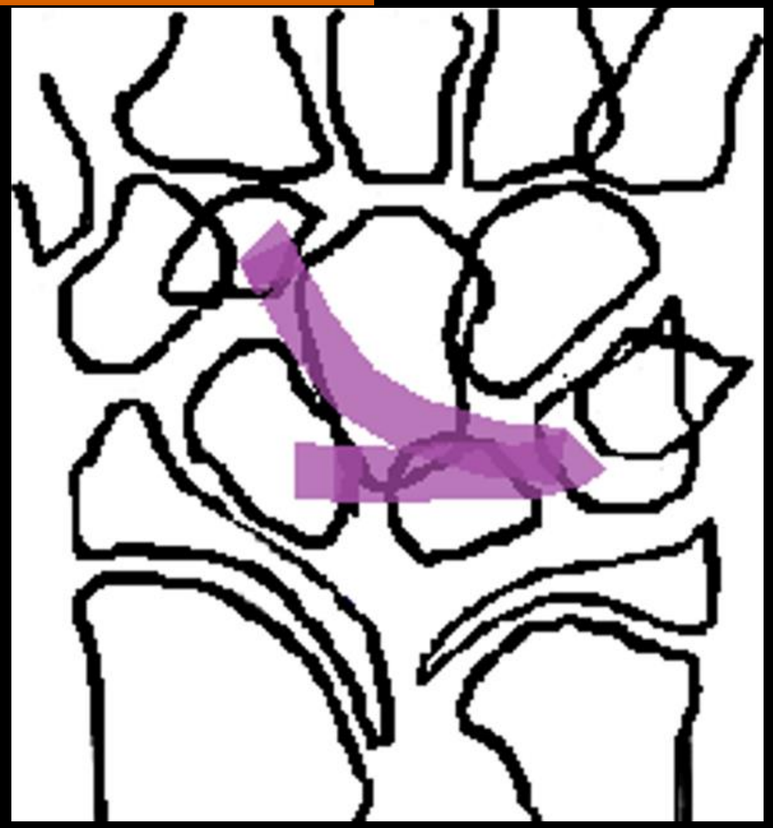

Extrinsic dorsal radiocarpal ligament (pink): part of the dorsal radiocarpal joint capsule and connects the dorsal radial rim with the lunate and triquetral boné.

Intrinsic dorsal intercarpal ligament (purple): extends from the dorsal tubercle of the triquetrum to the dorsal groove of the scaphoid. Also attaches to the dorsal aspect of the lunate and, 50% individuals, also attaches to the dorsal proximal trapezium.

HOW TO PROCEED INVESTIGATION?

FIRST STEP AND SECOND STEP: GILULA THREE CARPAL ARCS ON X-RAY

X-ray dorsal view of the left hand, disrupted Gilula arcs, if normal repeat it (second step) under stress and with a clenched fist.

THIRD STEP: DORSAL AND VOLAR DISPLACEMENT

X-ray lateral view of the left hand with dorsal displacement of the ulna and volar carpus and with a clenched fist.

HOW TO USE CORRECT CLASSIFICATION?

CLASSIFICATION AND FINDINGS

PATTERN

- **STATIC**
  - **DISSOCIATIVE (CID)**
    derangement within or between carpal bones in the same row
    - **DORSAL (DISI)** → Scapholunate (SL) Dissociation
    - **VOLAR (VISI)** → Lunotriquetral (LT) Dissociation
  - **NONDISSOCIATIVE (CIND)**
    derangement between the radius and proximal carpal row
    - **Direction**
  - **COMBINED**
    CID + CIND
    - **RADIOCARPAL**
      Ulnar translation, distal radius malunion
    - **MIDCARPAL**
    - → Rupture of extrinsec ligaments
  - **ADAPTATIVE**
    Instability in response to malalignment extrinsic to wrist
- **DINAMIC**

HOW TO TO MAKE THE DIAGNOSIS?

Carpal Instability Dissociative (CID)

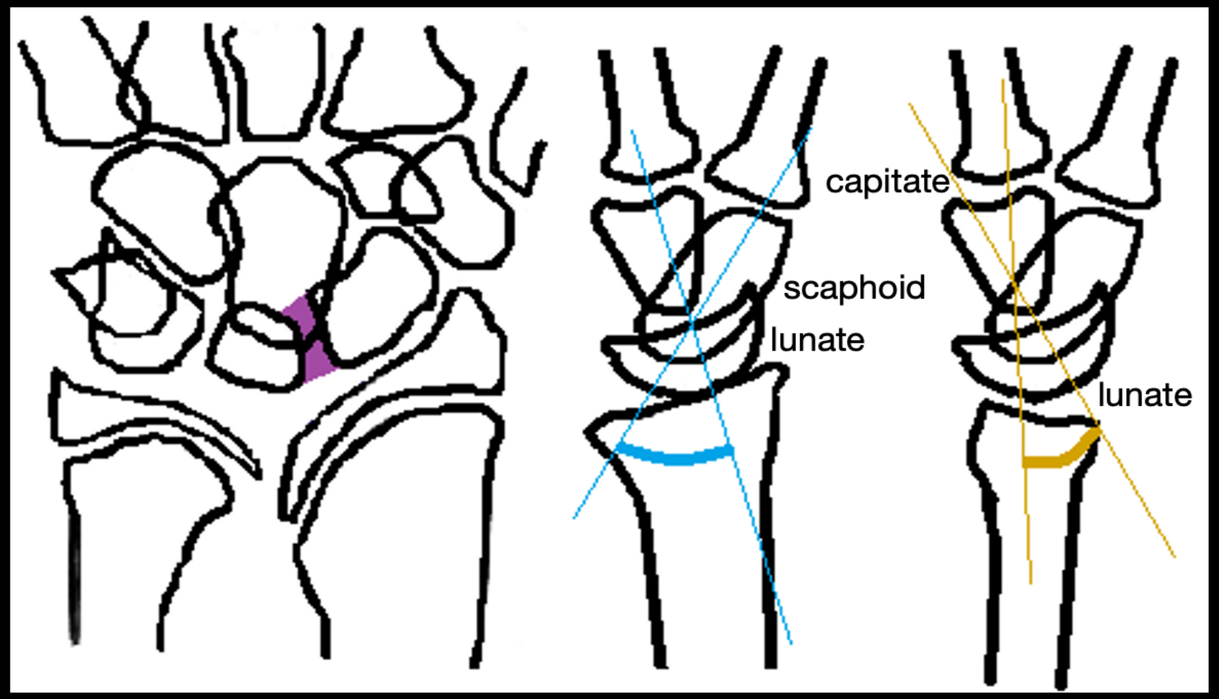

Dorsal Intercalated Segment Instability (DISI) - Disruption of the ligamentous link between the scaphoid and lunate (most common):

1) Widened scapholunate interval > 4 mm on PA view (purple area);
2) Lunate dorsiflexed and scaphoid tilted volarly with scapholunate angle >60˚ (blue).
3) capitolunate angle >30˚ (yellow).

Volar Intercalated Segment Instability (VISI) - Disruption of the ligamentous link between the scaphoid and lunate.

1) May show a widening between the capitate and the triquetrum
2) Scapholunate angle < *30˚;*
3) Capitolunate angle >30˚.

Carpal Instability Non Dissociative (CIND)

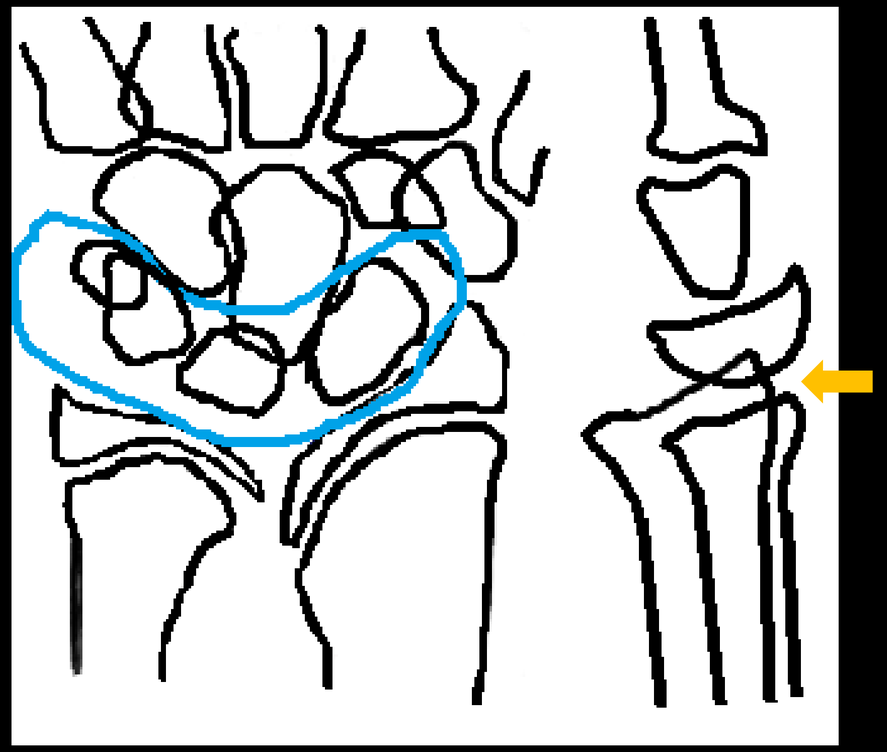

Widening of the radioscaphoid joint with ulnar shift of the proximal carpal row (blue). Radiographs of the wrist would depict ulnar translocation. Posterior displacement of the proximal carpal row in relation to the radius (yellow arrow).

JOINT HYPERMOBILITY SYNDROME

- Joint hypermobility is a unifying feature of the heritable disorders of connective tissue, a group of genetic disorders affecting connective tissue matrix proteins that classically include the Ehlers-Danlos syndrome, Marfan syndrome and osteogenesis imperfecta.
- In recent decades, it has become clear that there is a more common connective tissue disorder with a mixed phenotype of benign features that has been termed benign joint hypermobility syndrome.
- It has a highly variable presentation, but most patients draw attention because of their joint complaints due to the ability to move the joints beyond their normal range of motion.
- The laxity of joint ligaments predisposes to ligament injury and leads to joint instability, subluxation and dislocation and consequently is a risk factor for the development of premature osteoarthritis.

MIDCARPAL INSTABILITY NONDISSOCIATIVE - HYPERMOBILITY SYNDROME

DIFFERENTIAL DIAGNOSIS REVIEW – IS THERE ROOM FOR HYPERMOBILITY SYNDROME?

Madelung deformity
Trauma
Infection
Turner syndrome
Skeletal dysplasias
Hypermobility Syndrome

Inherited connective tissue disorders (Marfan, Osteogenesis imperfecta)

Related to Ehlers-Danlos

HYPERMOBILITY

Joint hypermobility spectrum disorders (HSD*)

SECONDARY (trauma, neurological, muscle diseases...)

CARPAL INSTABILITY x JOINT HYPERMOBILITY SYNDROME

- Diagnosis by physical examination (Beighton score, positive when >/= 5 joints are affected)
- Association with connective tissue diseases (Ehlers Danlos, Marfan, Osteogenesis imperfecta)
- Imaging tests may be normal initially
- Dynamic/effort study may sensitize the findings, usually associated with carpal instability with secondary ligament and bone injuries

WHAT TO EXPECT ?

Inherited connective tissue disorders / Ehlers-Danlos

Hemarthrosis (especially knees)
Recurrent dislocation
Early osteoarthritis
Triangular fibrocartilage disc rupture
Multiple ovoid calcifications (<1 cm) in the subcutaneous
Tissue ectopic ossification
Kyphoscoliosis
Spondylolisthesis
Arachnodactyly
Scoliosis
Reduction in bone density

OTHERS:
Intrathoracic formation of traumatic air cysts or pneumatoceles
Diaphragmatic hernia
Emphysema
Ectasias of the gastrointestinal tract
Arterial aneurysm formation
Dolichoectasia
Increased occurrence of arterial dissection (aortography contraindicated)

HYPERMOBILITY SYNDROME – EARLY AND LATE FINDINGS ON MRI

COMMON FINDING: TRIANGULAR FIBROCARTILAGE DISC RUPTURE

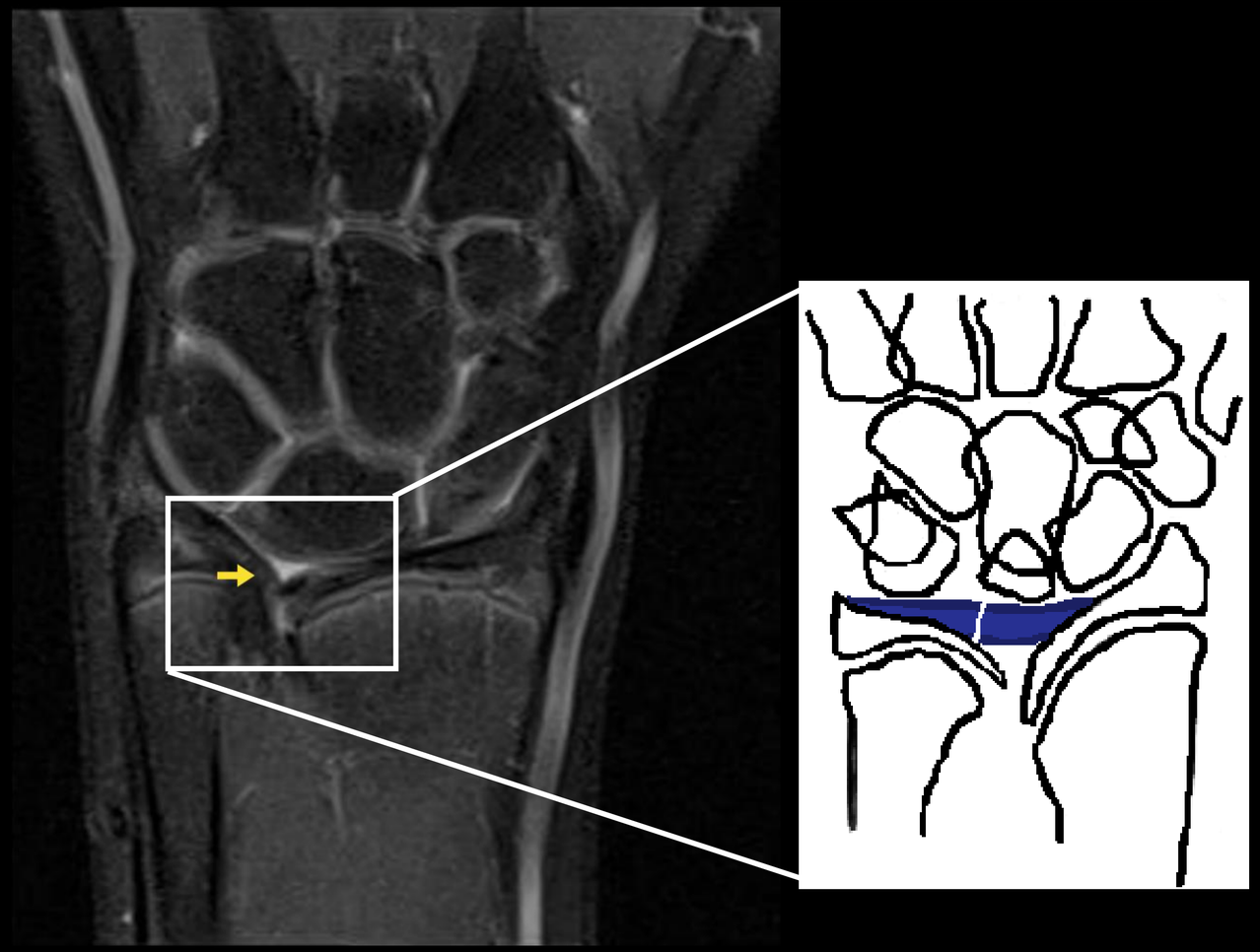

Left hand MRI - Coronal proton density fat saturation sequence. Degeneration early than 30 Years may indicate chronic stress by hypermobility

DIFFERENCE BETWEEN EXAMES

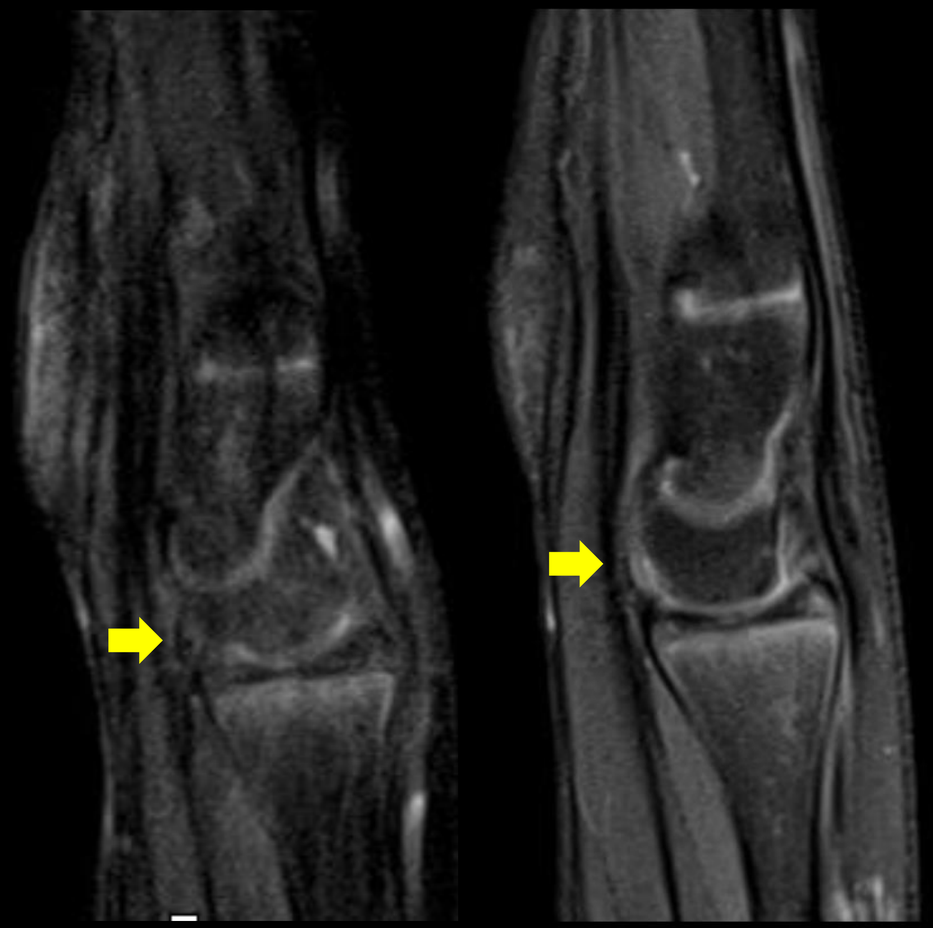

SET/13th SET/16th

Left hand MRI - Lateral proton density fat saturation sequence, note *volar carpus deviation that changes between exams.*

COMPLICATIONS AND JOINT SEQUELAE

Scapholunate advanced collapse (SLAC wrist)

Arthropathic changes of the radioscaphoid joint evident by narrowing of its joint space and subarticular sclerotic bony change and remodeling involving the scaphoid bone.

Scapholunate dissociation with increased distance between the scaphoid and the lunate bones. Proximal migration of the capitate bone.

Degenerative changes of the radioscaphoid and to less extent the intercarpal joints.

The lunate is directed in the dorsal direction with respect to the capitate (DISI).

Scaphoid nonunion advanced collapse (SNAC wrist)

Non-union scaphoid fracture.

Inferior migration of the capitate.

Advanced degenerative changes in the radioscaphoid compartment.

DIFFERENTIAL DIAGNOSIS

Madelung deformity

Anteroposterior wrist views demonstrate an increased radial inclination, proximal, and volar migration of the lunate with triangulation of the carpus and positive ulnar variance.

On lateral X-rays reveal volar subluxation of the carpus and dorsal subluxation of the distal ulna.

DIFFERENTIAL DIAGNOSIS

Trauma

Complete transverse scaphoid neck fracture without significant fragment deviation distal, with subcortical sclerosis of the bone fragments, presence of subcortical cysts at the fracture focus, without signs of bone callus formation (pseudoarthrosis). Sequelae of a metaepiphyseal fracture of the radius.

Dorsal inclination of the lunate. Degenerative radiocarpal changes, with irregularity of the joint surfaces, sclerosis and small subchondral cysts.

CONCLUSION

TAKE HOME MENSSAGE:

- Uncommon: carpal instability in the pediatric belt, especially when it is not secondary to trauma.
- Knowledge of differential diagnosis and steps to make correct diagnosis, remembering among the possibilities the Hypermobility Syndrome.

REFERENCES

1. Boudreau PA, Steiman I, Mior S. Clinical management of benign joint hypermobility syndrome: a case series. J Can Chiropr Assoc. 2020 Apr;64(1):43-54.
2. Kumar B, Lenert P. Joint Hypermobility Syndrome: Recognizing a Commonly Overlooked Cause of Chronic Pain. Am J Med. 2017 Jun;130(6):640-647.
3. Hakim A, Grahame R. Joint Hypermobility. Best Pract Res Clin Rheumatol. 2003;17(6):989-1004.
4. Castori M, Hakim A. Contemporary approach to joint hypermobility and related disorders. Current Opinion in Pediatrics. 2017;29(6)640-649.
5. Grunz JP, Gietzen CH, Grunz K, *et al*. Imaging of Carpal Instabilities. Fortschr Röntgenstr. 2021;193:139-150.
6. Wolfe SW, Elias MG, Kitay A. Carpal instability nondissociative. J Am Acad Orthop Surg. 2012 Sep;20(9):575-85.