Back
Help Thaisa Gomes Logout

RSNA 2021
REDEFINING RADIOLOGY
November 28 to December 2

Clinical Challenge of Gluteal Pain: How Can the Radiologist Help?

Thaisa Lazari Gomes
Glauber Sartorio Menegardo
Guilherme Soares de Oliveira Wertheimer
Daniel Miranda Ferreira
Vinicius Silles Brandão Machado
Sérgio San Juan Dertkigil
Eduardo José Mariotoni Bronzatto

UNICAMP

Department of Radiology, State University of Campinas (Unicamp), Brazil

RCC
Radiologia Clínica de Campinas

José Michel Kalaf Research Institute, Campinas, Brazil

The authors have no conflict of interest to disclosure in this presentation

Introduction

Gluteal pain is a frequent complaint in clinical settings, it is usually related to sciatica and caused by a herniated disk compressing the nerve roots of L4-S1. However, 10% of sciatic pain has a nondiscogenic etiology, related to neural pathway in intrapelvic or subgluteal spaces.

Sciatic compression is not the only cause of gluteal pain. The sensory branches of the **Lombossacral Plexus (L2-S1)** innervate the hip and inferior libs, perineum and gluteal region, being potentials sites for neural conflicts.

Deep gluteal pain syndrome is a recently classified entity that represents a compression of the sciatic or pudendal nerve in the deep gluteal space, which may be secondary to tumor compressions, syndromes, inflammatory and infectious processes, post-surgical complications, gynecological pathologies, neurovascular conflicts, and other diagnoses. *The clinical presentation of these less frequent pathologies can be mistaken with lumbar disc herniation, delaying its diagnosis and treatment.*

Objectives

Review the anatomical structures of the **subgluteal space** ;

Demonstrate **peripheral neuropathy** different presentations ;

Expose **non-discogenic gluteal pain** causes;

Discuss **non-neurogenic gluteal pain** differential diagnoses.

Neuropathy Findings

The nerve has an oval shape and is composed of bundled fascicles between connective tissue.

On T1 sequences, the nerve is isointense or slightly hyper intense to the muscle and hypointense to the vessels. We can see low sign connective tissue separating the fascicles and preservation of the high signal of perineural fat.

In STIR sequences (inversion recovery sequence), sensitive to fluids, edema or other neural pathological processes appear with hyperintense sign.

Neural injury is suggest by increased signal, blurring of the perifascicular fat, loss of the normal fascicular appearance, enlargement or other morphologic changes.

Sequence	T1	STIR
Normal Nerve		
Enlargement		
Increased signal		
Loss of the normal fascicular pattern		
Focal alterations in nerve contour		
Blurring of the perifascicular fat		

Sequence	T1	STIR
Normal Nerve		

Enlargement

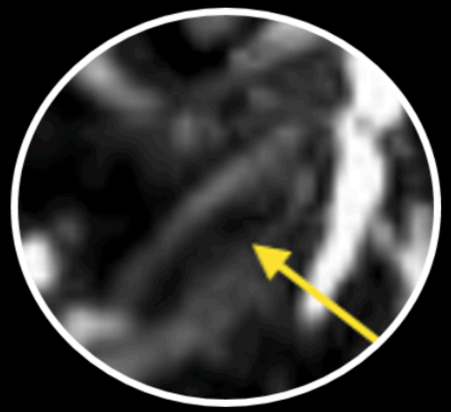

Increased signal

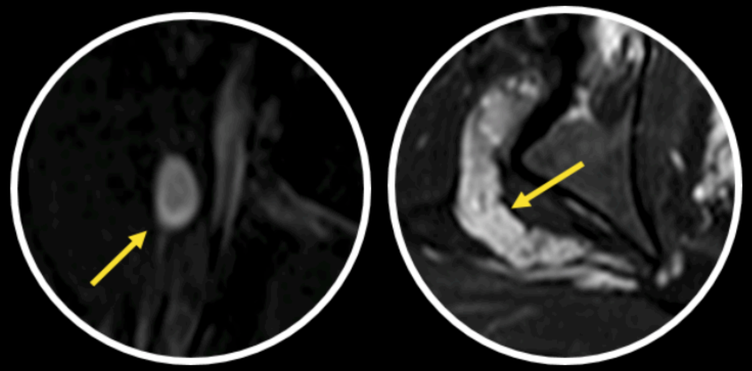

Loss of the normal fascicular pattern

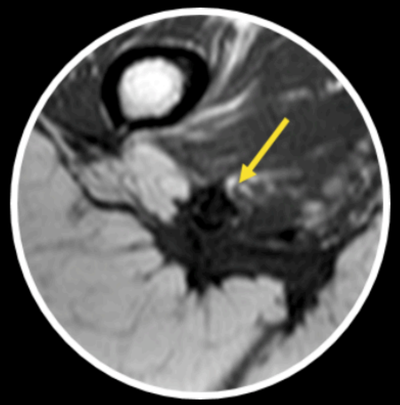

Focal alterations in nerve contour

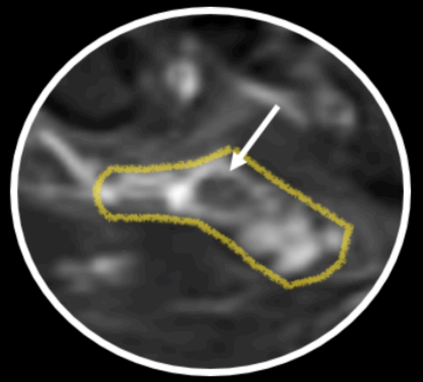

Blurring of the perifascicular fat

HIGHTLIGHTS OF THE SUBGLUTEAL SPACE

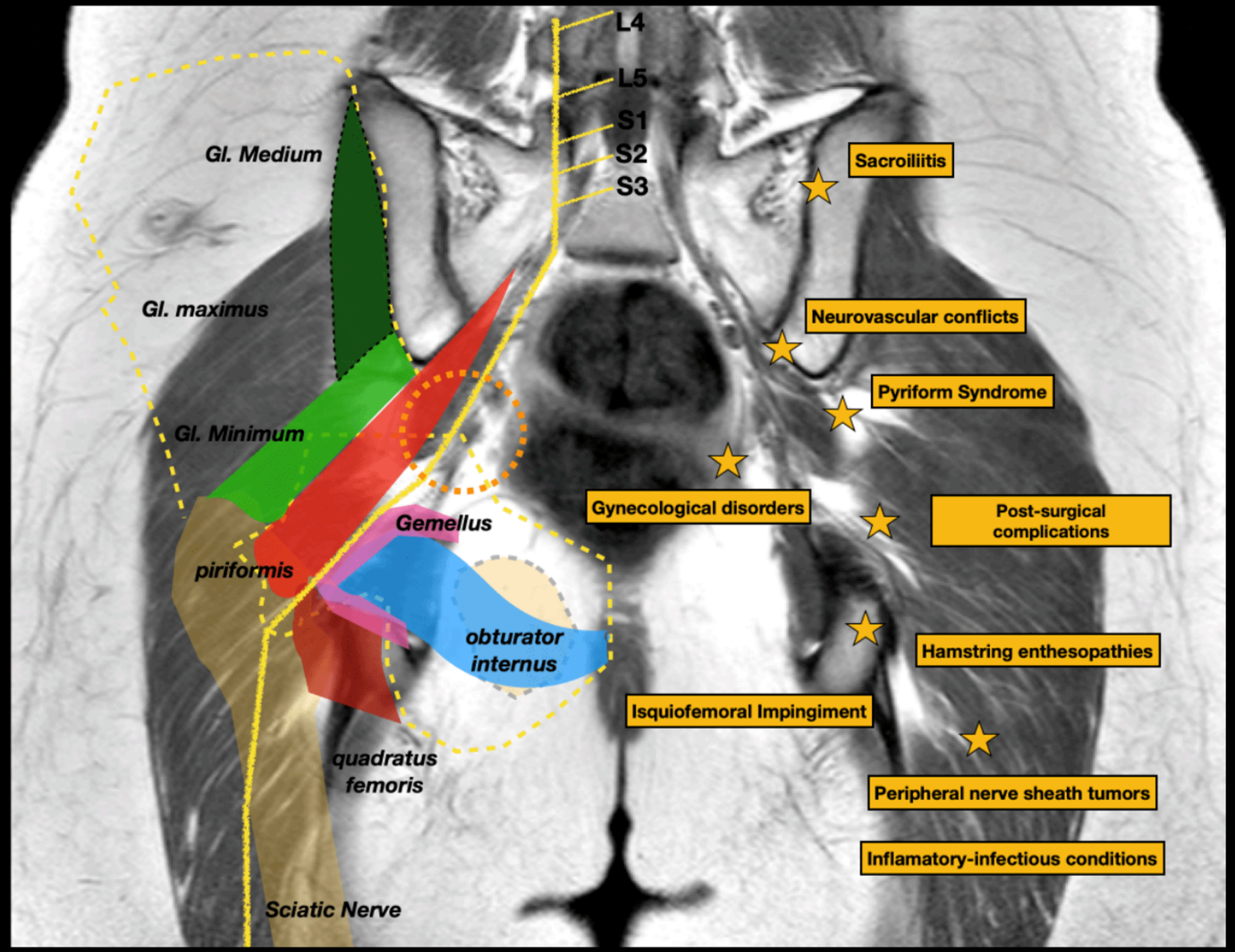

The subgluteal space is the cellular and fatty tissue located between the middle and deep gluteal aponeurosis layers.

The anatomical limits are:
- ***posterior:*** gluteus maximus muscle.

- ***anterior:*** posterior border of the femoral neck, greater and lesser trochanters. At its inferior margin it continues into and with the posterior thigh.

- ***lateral:*** it is demarcated by the *linea aspera* and the lateral fusion of the middle and deep gluteal aponeurosis layers extending up to the tensor *fasciae latae* muscle via the iliotibial tract.

- ***medial:*** margin is composed of the greater and minor sciatic foramen.

Within the space, from superior to inferior, we have the muscles: piriformis, superior gemellus, obturator internus, inferior gemellus and quadratus femoris.

Introduction

Non-discogenic neurogenic gluteal pain:

- tumor compressions
- piriformis syndrome
- inflammatory and infectious processes
- post-traumatic lesions
- post-surgical complications
- gynecological pathologies
- neurovascular conflicts

Non-neurogenic gluteal pain (or sciatic-like):

- Sacroiliitis
- Stress fractures
- Hamstring enthesopathies
- Ischiofemoral Impingiment
- Inflammatory and infectious processes
- Post-traumatic lesions

PRIMARY SCIATIC NERVE LESIONS

EXPANSIVE LESIONS

Schwannoma

Prevalence:
- the most common benign peripheral nerve sheath tumor
- single (90%)
- if multiples normally associated with type 2 neurofibromatosis (third decade)

Imaging Findings:
-T1: hypointense
-T2: hyperintense or heterogeneous
-T1 C+(Gd): intense enhancement

* fascicular sign (suggests neurogenic origin lesion)
* cystic and fatty degeneration is common

Neurofibroma

Prevalence:
- less common
- plexiform neurofibroma subtype is pathognomonic of type 1 neurofibromatosis (associated with malignant transformation)

Imaging Findings:
-Neurofibroma: findings similar to schwannoma and often indistinct
* target sign is more common in neurofibromas but can be found in schwannoma - hyperintense rim and central area of a low signal

-Plexiform neurofibroma: usually diagnosed in early childhood. T1/T2: diffusely involve long nerve segments and its branches, often extending beyond the epineurium into the surrounding tissue

Intraneural Ganglion

A mucinous cyst within the epineurium of a nerve, walled off by a fibrous layer. It is a rare entity, even rarer in the roots of the lumbar plexus. Most commonly in the peroneal nerve around the fibular head

Imaging Findings:
- High-signal cystic formation in T2-weighting images
- lack of enhancement
- usually seen a tail extending to the hip joint or facet
- can be mistaken as a cystic schwannoma (Antoni B cells)

PRIMARY SCIATIC NERVE LESIONS

EXPANSIVE LESIONS

Schwannoma

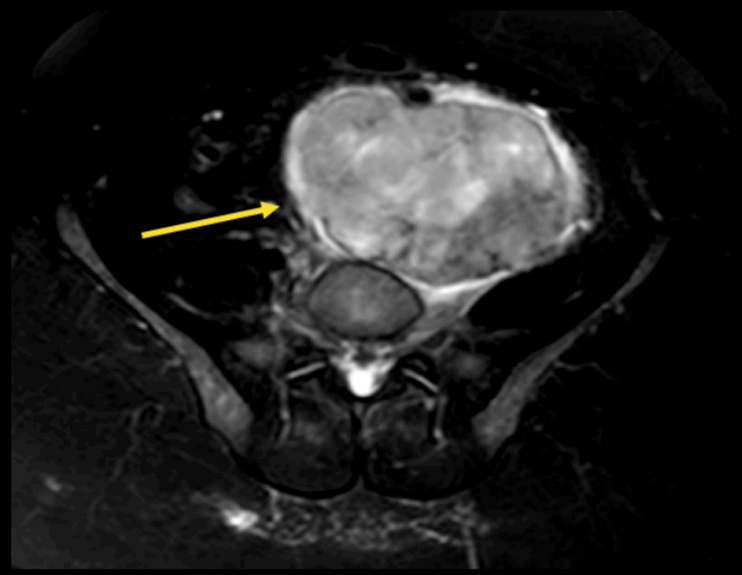

Axial STIR recovery-weighted sequence

40-year-old female with hypervascularized and heterogeneous lesion on T2FAT MRI sequence corresponding to left L5 root schwannoma (arrow)

Neurofibroma

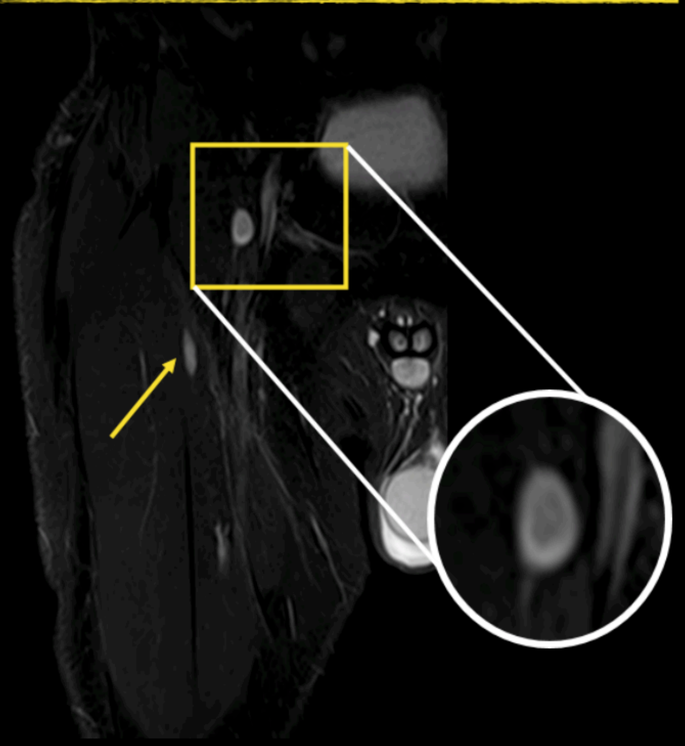

Coronal STIR recovery-weighted sequence

32-year-old female diagnosed with NF-1 demonstrating multiple hyperintense lesions in peripheral nerves (arrow). The largest one in the sciatic nerve outlining target signal (circle)

Plexiform Neurofibroma

Enlargement of the left gluteal region in a 2-year-old male patient by an expansive formation (arrows) in the sciatic nerve related to type 1 neurofibromatosis

Coronal STIR recovery-weighted sequence

PRIMARY SCIATIC NERVE LESIONS

EXPANSIVE LESIONS

Intraneural Ganglion

High-signal cystic formation in T2-weighting in the left sciatic nerve (arrow). Observe the mass effect showed shifting the fibers peripherally. A tail extending to the hip joint or facet **is** partially seen *(arrow head)*.

- Can be mistaken as a cystic schwannoma
- Differential diagnosis with nerve abscesses related to Hansen's disease

Axial Fast short-tau inversion recovery

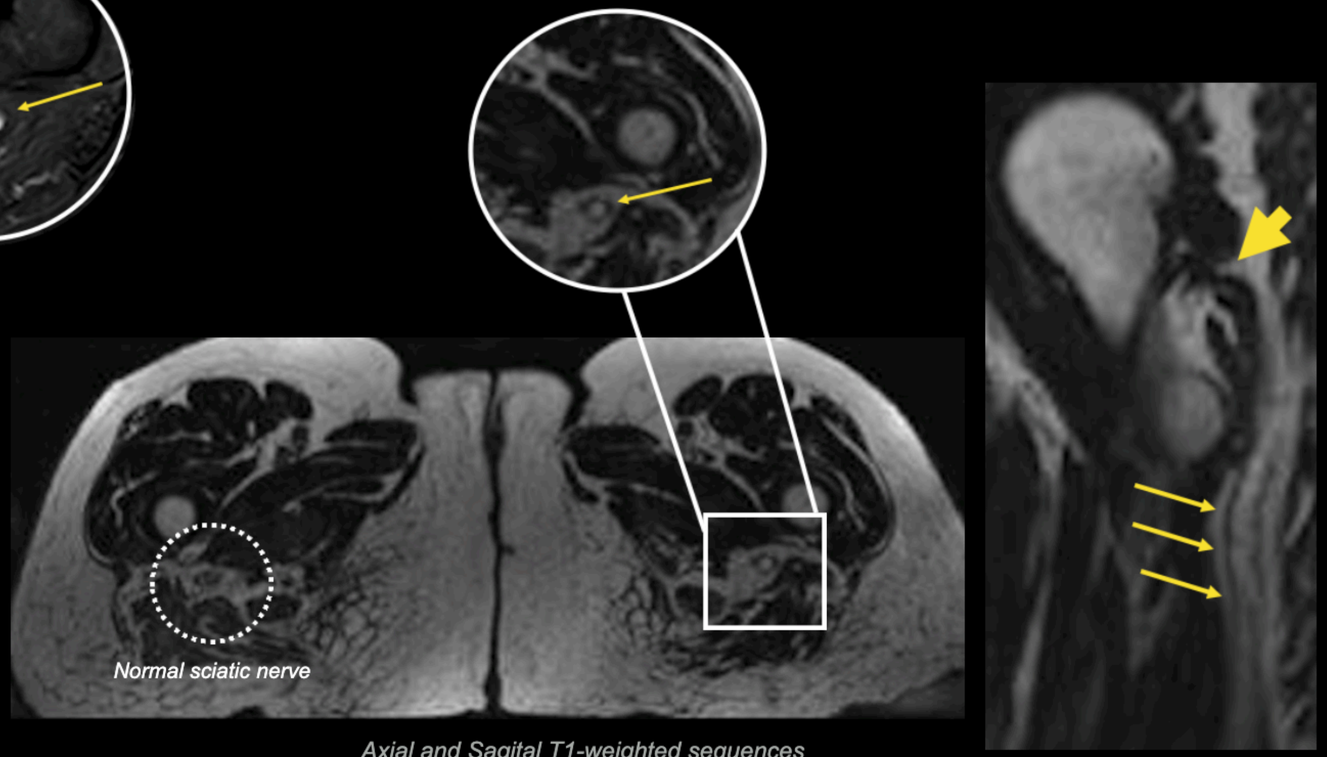

Axial and Sagital T1-weighted sequences

EXTRANEURAL LESIONS

EXPANSIVE LESIONS

Intrapelvic Tumors

Middle aged woman complaining of gluteal pain on the left side due to tumoral lesion intrapelvic involving of the left S1 root (arrow). Note the nerve contour alterations, neural enlargement and loss of the normal fascicular appearance.

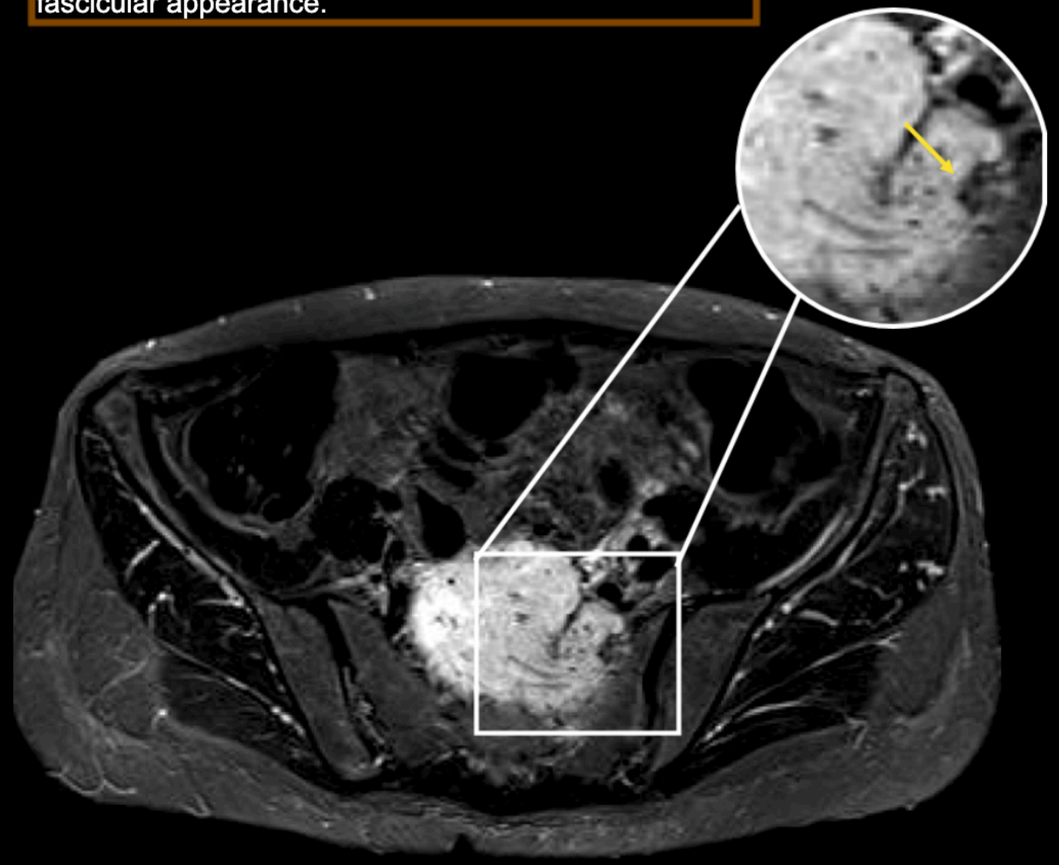

Axial Fast short-tau inversion recovery sequence

Metastases

88-year-old woman with left renal cell carcinoma with hipervascularized metastases to the right L5 nerve root (dashed circle), liver (arrow) and right adrenal (square).
Note the similar sign intensity of all lesions.

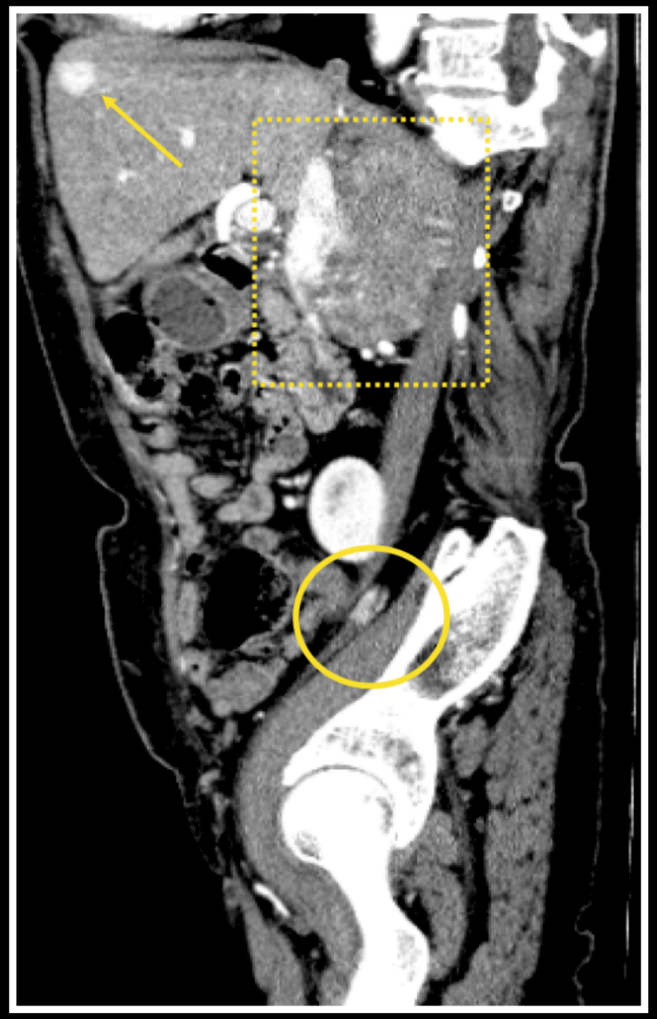

Axial and Sagital computed tomography image in the arterial phase,

GYNECOLOGICAL PATHOLOGIES

EXPANSIVE LESIONS

Endometriosis

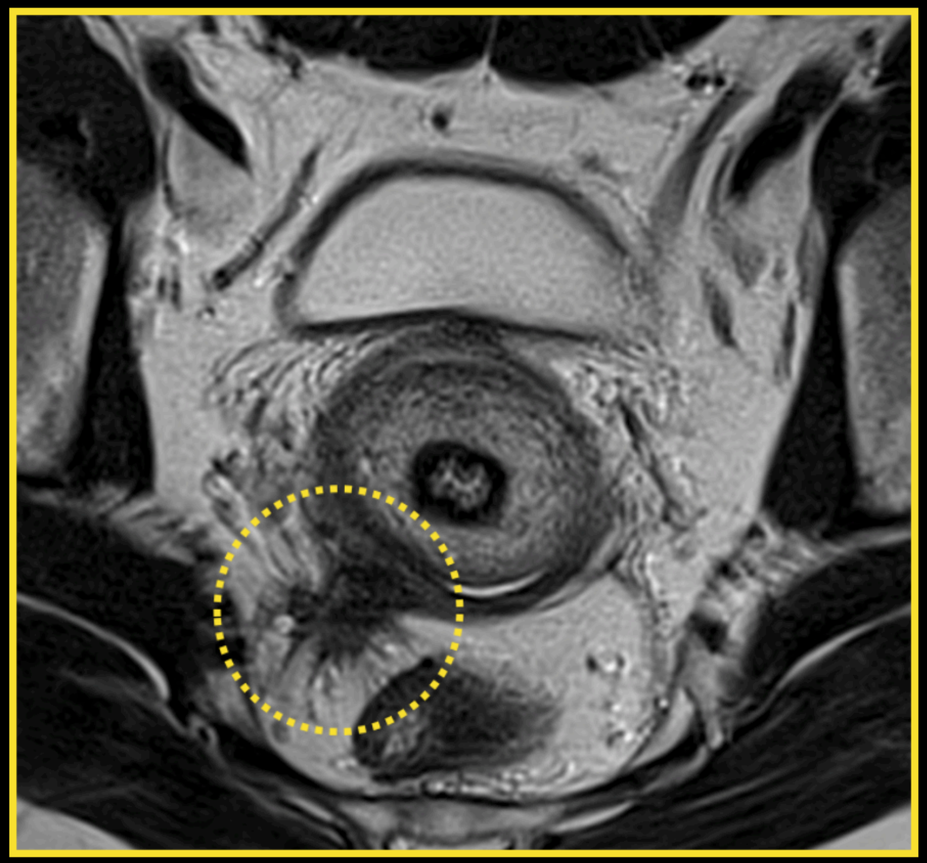

Introduction: sciatic nerve involvement commonly from direct extension of deeply infiltrative rectovaginal disease through the lateral pelvic sidewall. Less commonly, can be present in isolation, without any apparent endometriosis in the pelvic peritoneal cavity.

Prevalence: infrequently, endometriosis infiltrate pelvic nerves and cause sciatic neuropathy or lumbosacral plexopathy.

Clinical Findings: cyclical worsening of pain

Imaging Findings:
-Fibrous or vascular bundles in the deep gluteal space relating to signs of neuropathy.

GYNECOLOGICAL PATHOLOGIES

EXPANSIVE LESIONS

Endometriosis

35-year-old woman with retractable endometriotic tissue in the right retrocervical region with low signal on T2 (Left Image - circle). FATSAT sequence shows high-signal foci corresponding to hematic content (orange arrow).

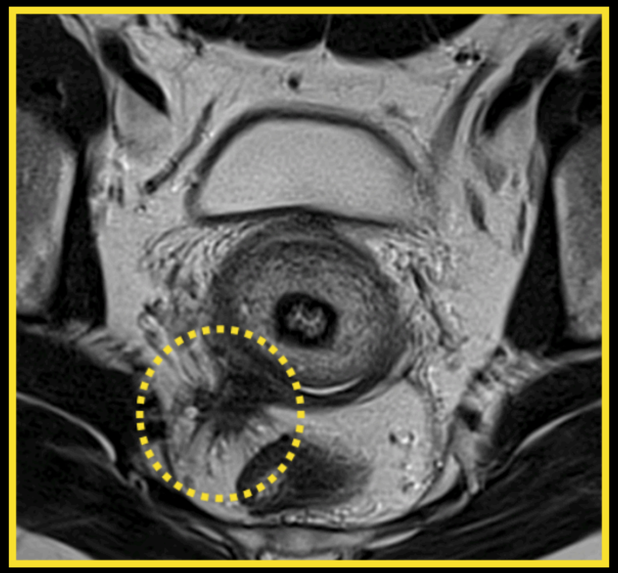

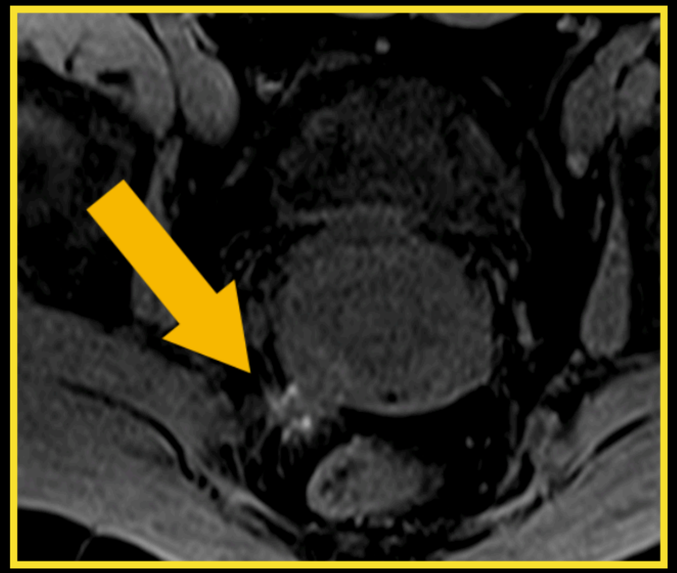

Endometriotic focus with similar characteristics in the right sciatic (orange arrows) which is thickened and retractable.
Blood products representing a high signal in T1FS-Gd (Left image).
Normal left sciatic and nerve root (blue arrows)

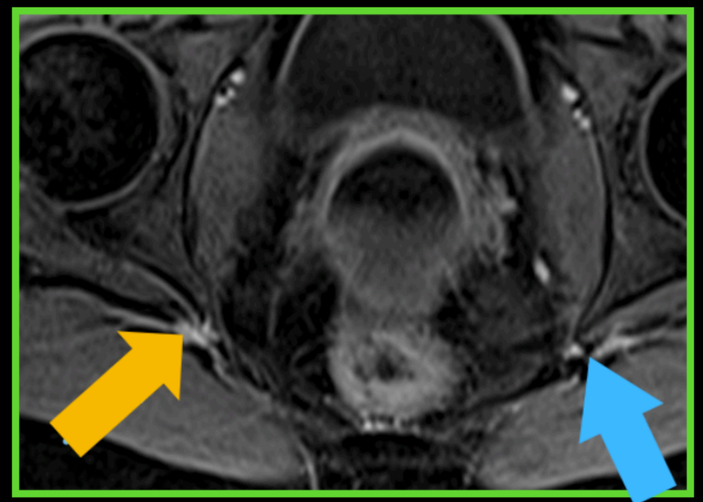

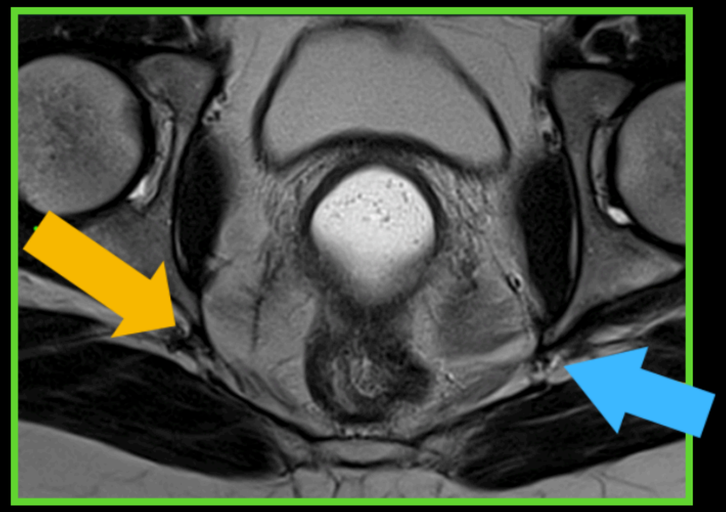

Curtesy from Dr Antonio Eustaquio Dantas Silva Junior

NEURAL ENTRAPMENT

Neurovascular Entrapment

Coronal T1-W SPACE shows tortuous left internal iliac artery causing compression of the L1 root against the sacral wall (arrow).
In the highlighted circle note the increased left L1 root signal (arrow)

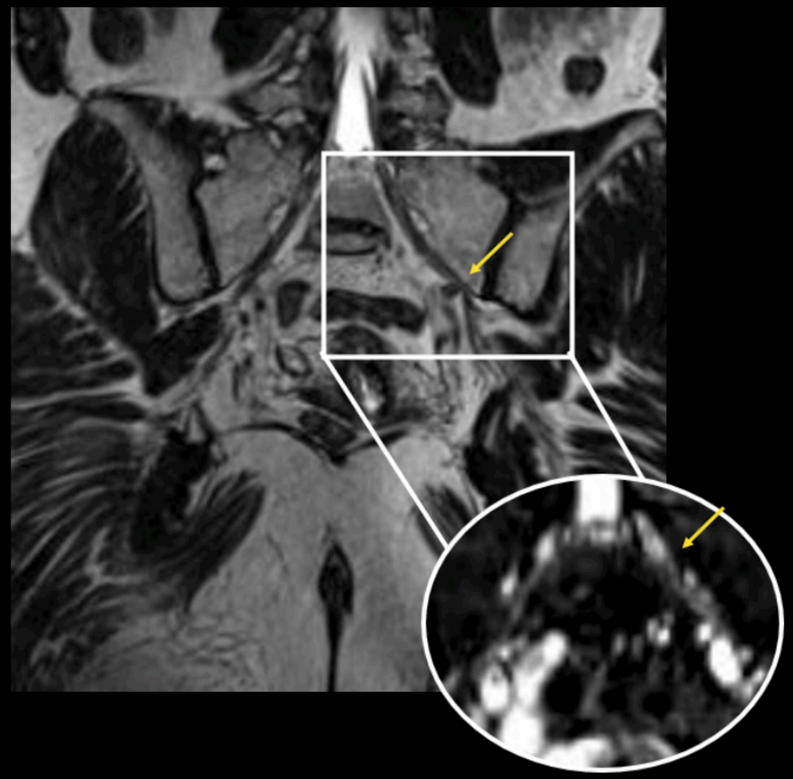

Circle: *Coronal Fast short-tau inversion recovery (SPACE)*

Introduction: **compression of the sciatic nerve by an abnormal fibrous/fibrousvascular band.**

Prevalence: **rare cause of Deep Gluteal Pain.**

Clinical Findings: **lower back pain and sciatica syndrome.**

Imaging Findings:
-Fibrous or vascular bundles in the deep gluteal space relating to signs of neuropathy.

NEUROVASCULAR CAUSES

NEURAL ENTRAPMENT

Abnormal path pelvic vessels

Circle: Coronal Fast short-tau inversion recovery

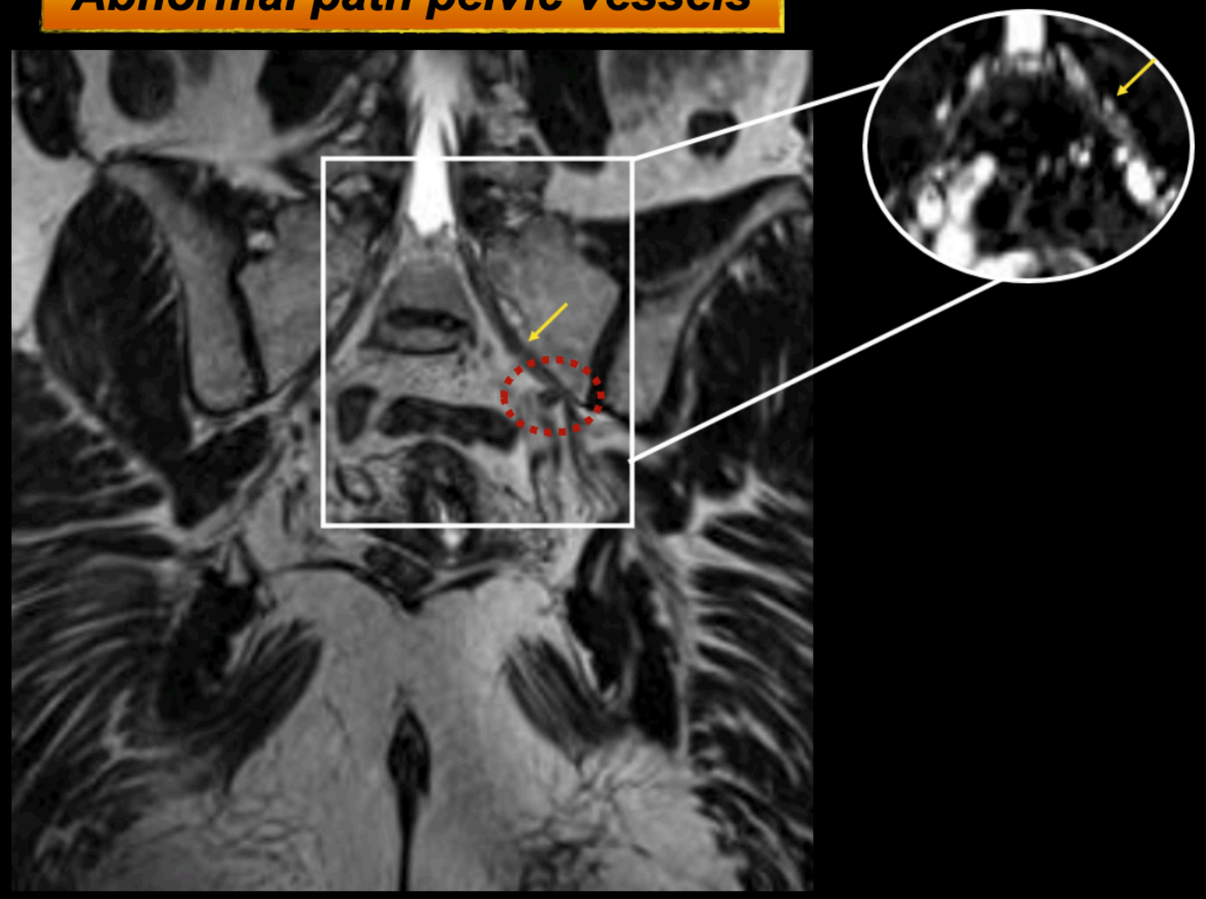

Coronal T1-W SPACE shows tortuous left internal iliac artery (red circle) causing compression of the L1 root against the sacral wall (arrow).
In the highlighted circle note the increased left L1 root signal (arrow)

Gluteal varices

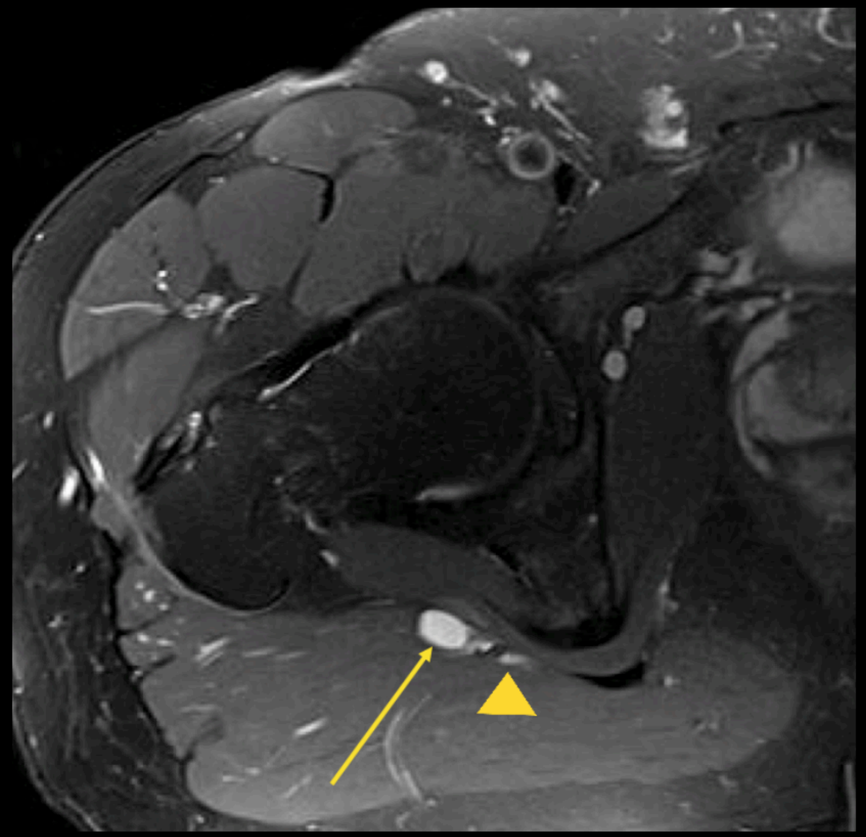

Axial fast short-tau inversion recovery image shows right inferior gluteal vein varix (arrow) compressing the lateral sciatic nerve (arrow head).

NEURAL ENTRAPMENT

Piriformis Syndrome

Coronal T2-weighted SPACE

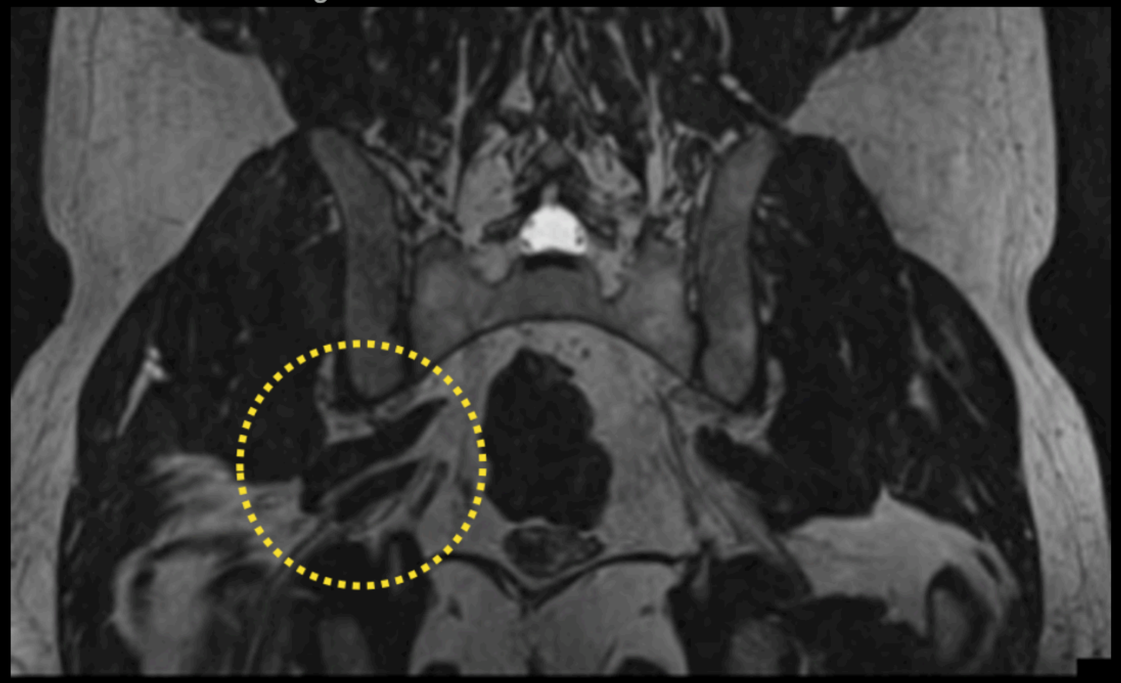

Introduction: compression of the sciatic nerve by an abnormal piriformis muscle.

Prevalence: some studies show it to be up to 25% of Deep Gluteal Pain causes.
Female to Male incidence 6:1.

Clinical Findings: buttock pain, pain aggravated on sitting, external tenderness near the greater sciatic notch.

Imaging Findings:
Abnormal condition of the Piriformis muscle
-Primary causes: hypertrophy and anatomical variations
-Secondary causes: trauma, inflamation, infection, etc

NEURAL ENTRAPMENT

Piriformis Syndrome

Primary causes: intrinsic problems within the muscle
-Piriformis hipertrophy
-Anatomical variations* between the relationship of the sciatic nerve and piriformins, the most frequent:
  -The sciatic nerve passes beneath the piriformis (85%).
  -The sciatic nerve peronial portion pierces the piriformis while the tibial components passes distal to it (10%).

** It has been suggested that anomalous variants may pose a risk for the development of the deep gluteal syndrome, but the association remains unproven.*

Secondary causes: irritation from the sacroiliac joint or adjacent mass
-Post traumatic muscle contusion.
-Overuse of the piriformis muscle in athletes (runners and bikers)
-Inflammation and Infectious diseases
-Tumoral lesions
-Constrictive fibrous bands

NEURAL ENTRAPMENT

Piriformis Syndrome

Coronal T2-weighted SPACE

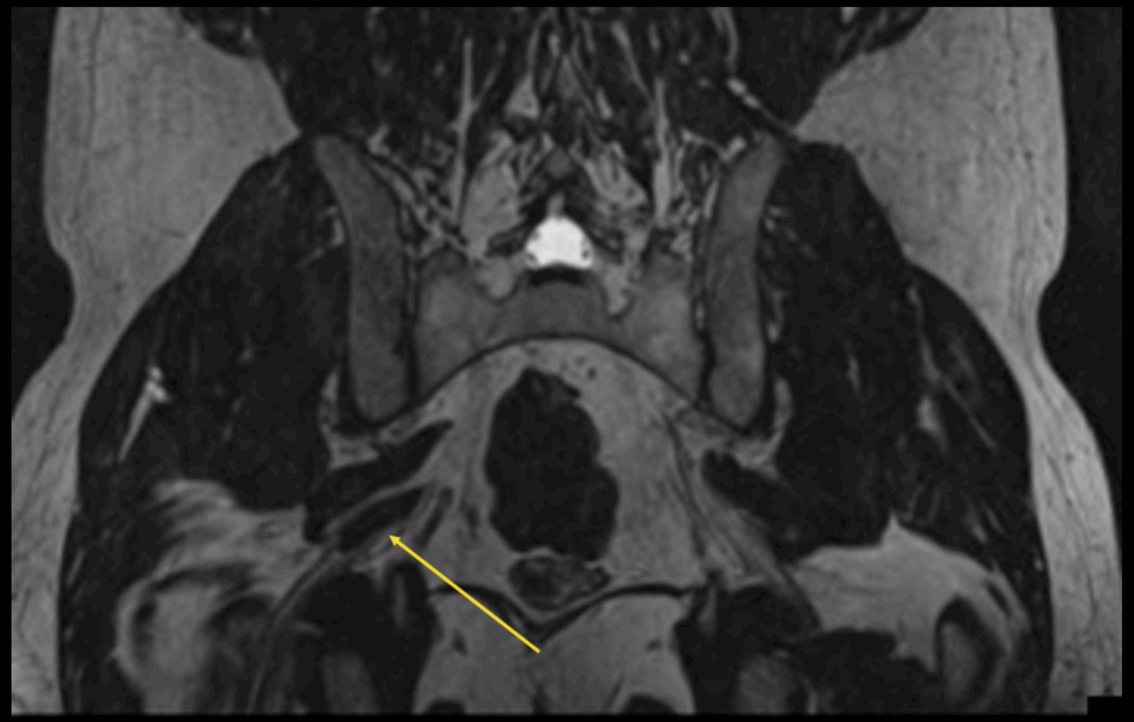

Middle-aged woman suffering from persistent right gluteal pain even after lumbar surgery that worsens when sitting.
The arrow demonstrates an inferior accessory belly of the right piriformis muscle.

Coronal Fast short-tau inversion recovery (SPACE)

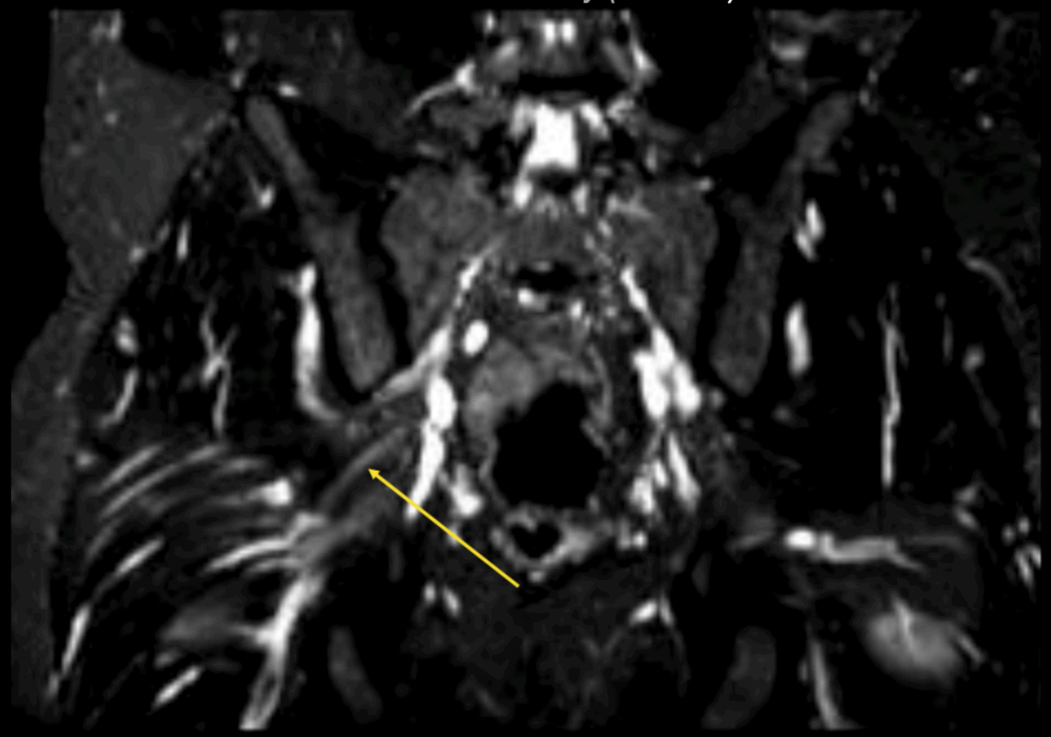

Same patient showing sciatic nerve peronial fibers enlargement and signal increase (arrow)

POST-SURGICAL COMPLICATIONS

Traumatic Neuroma

40-years-old male, 1 year after right hip disarticulation surgery leads to persistent ispilateral neuralgia. We can see a large stump neuroma causing the pain (arrow)

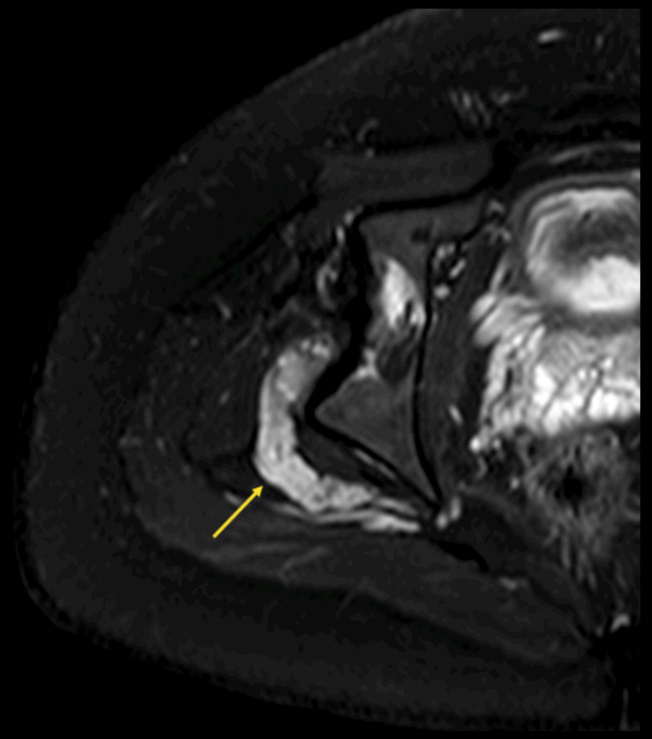

Axial T2-weidghed Fat-saturated sequence

Fibrotic bands

50-year-old male in postoperative control of resection of gluteus liposarcoma presents retractable fibrotic tissue involving the sciatic nerve, which is thickened and with slight signal increase in T2WI (arrows)

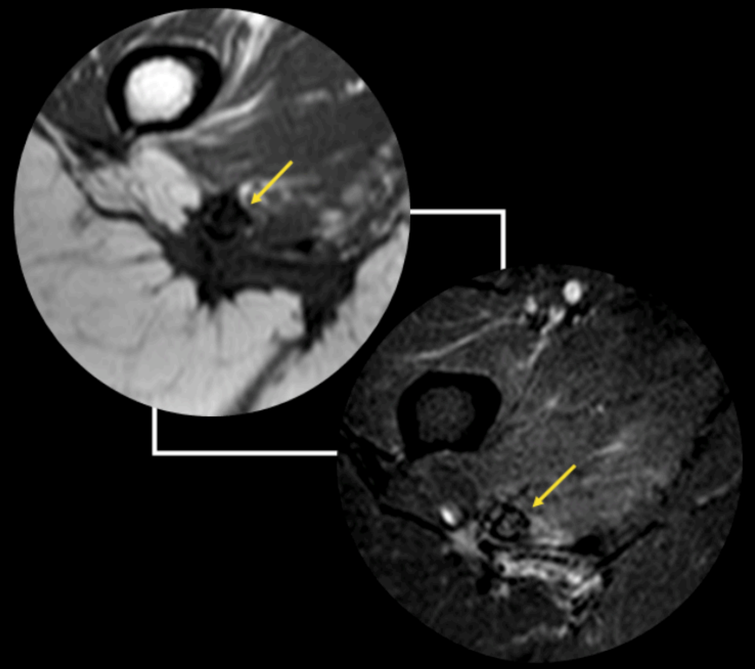

Axial T1-weidghed and T2 Fat-saturated images

Thrombophlebitis

Woman with prolonged surgical time develops gluteal vessel thrombophlebitis (green circle). The edema-sensitive sequence shows the inflammatory process involving the sciatic nerve and causing reactive sciatica. The nerve is thickening and clouding the perifascicular fat (arrow and blue circle).

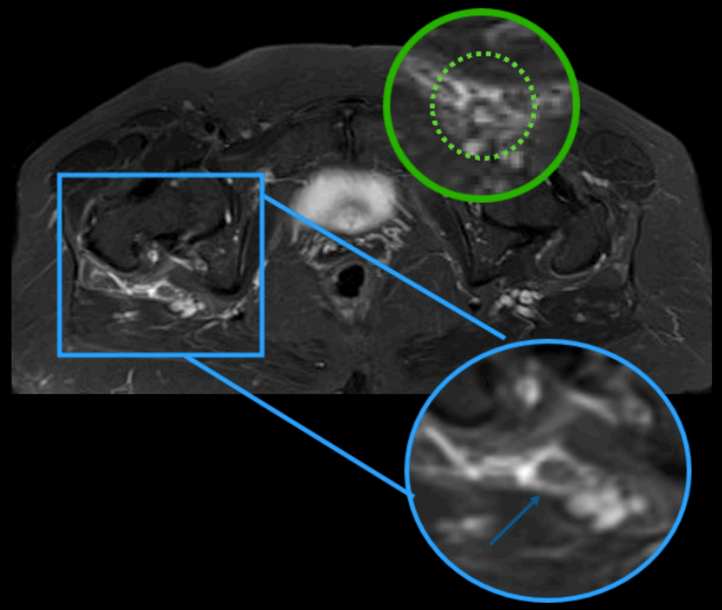

***Axial** Fast short-tau inversion recovery sequence*

DIFFERENTIAL DIAGNOSES OF GLUTEAL PAIN

Introduction:

Two different mechanisms can justify non-neurogenic gluteal pain (or sciatic-like):

The sacroiliac joint and hips can generate referred pain in the gluteus and lower limbs because they share the same area of somatic innervation as sciatica.

Sacroiliac and hips joints pathologies can generate inflammatory mediators and secondarily affect nearby spinal branches (reactional neuritis), due to close anatomical relationship between them.

Back
Help Thaisa Gomes Logout

DIFFERENTIAL DIAGNOSES OF GLUTEAL PAIN

Stress Fracture

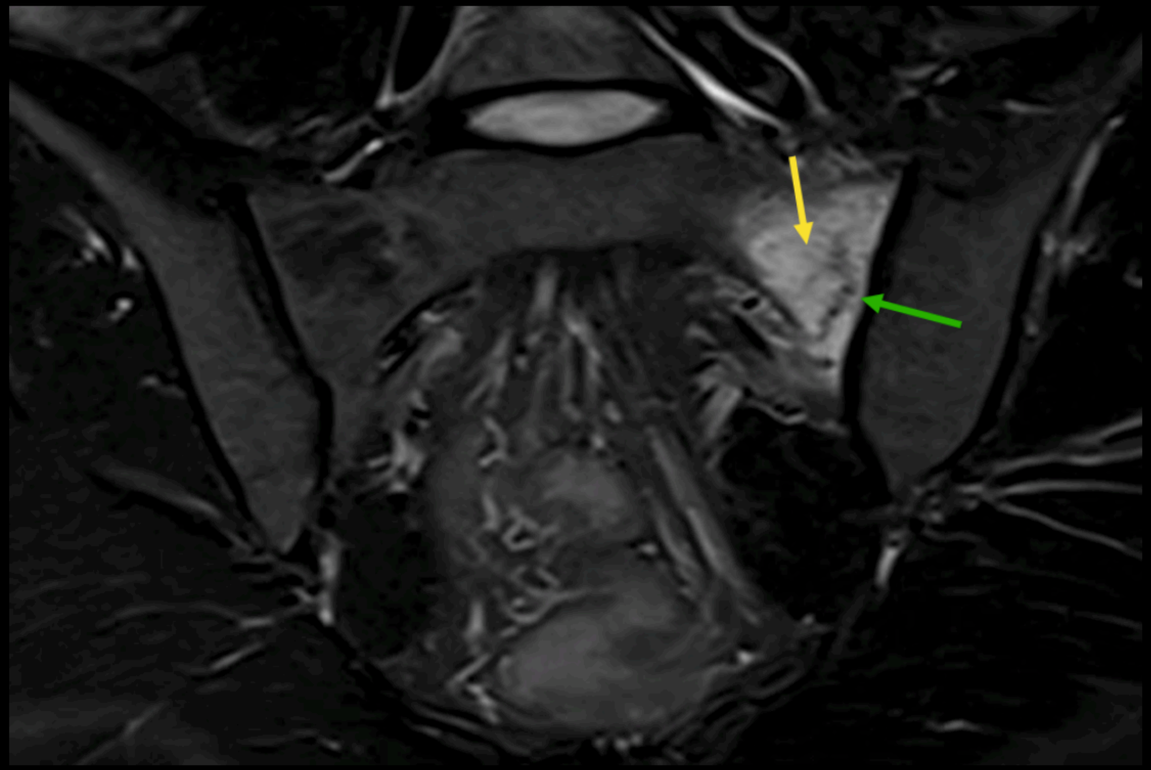

Female runner presenting with buttocks pain.
T2-weighting shows stress fracture (green arrow) and bone edema in the left sacral wing (yellow arrow).

Sacroiliitis

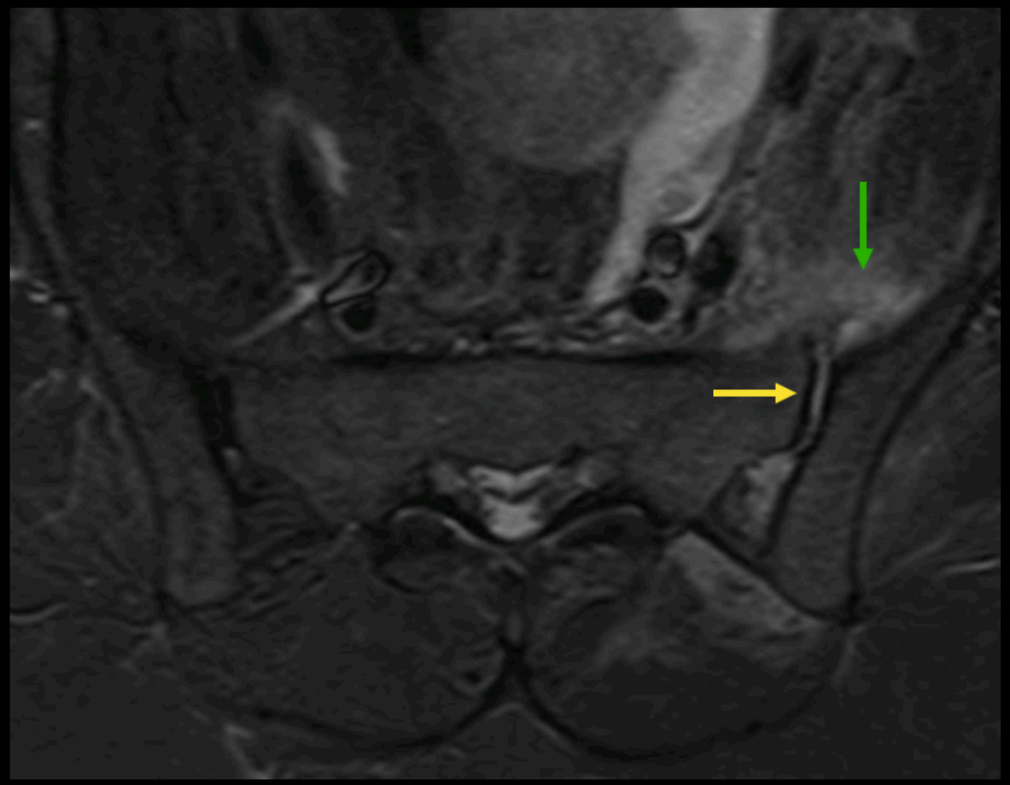

T2-weighting demonstrate a case of left infectious sacroiliitis: joint effusion and synovitis (yellow arrow) with soft tissue edema (green arrow).

DIFFERENTIAL DIAGNOSES OF GLUTEAL PAIN

Inflammatory Sacroiliitis

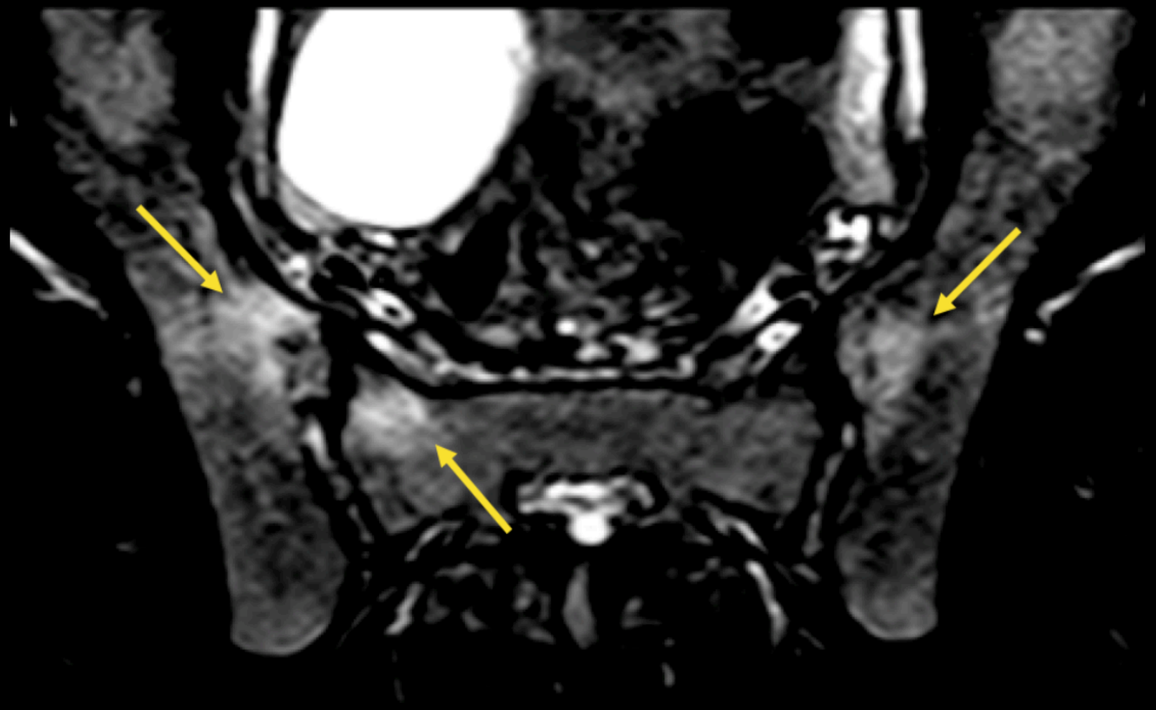

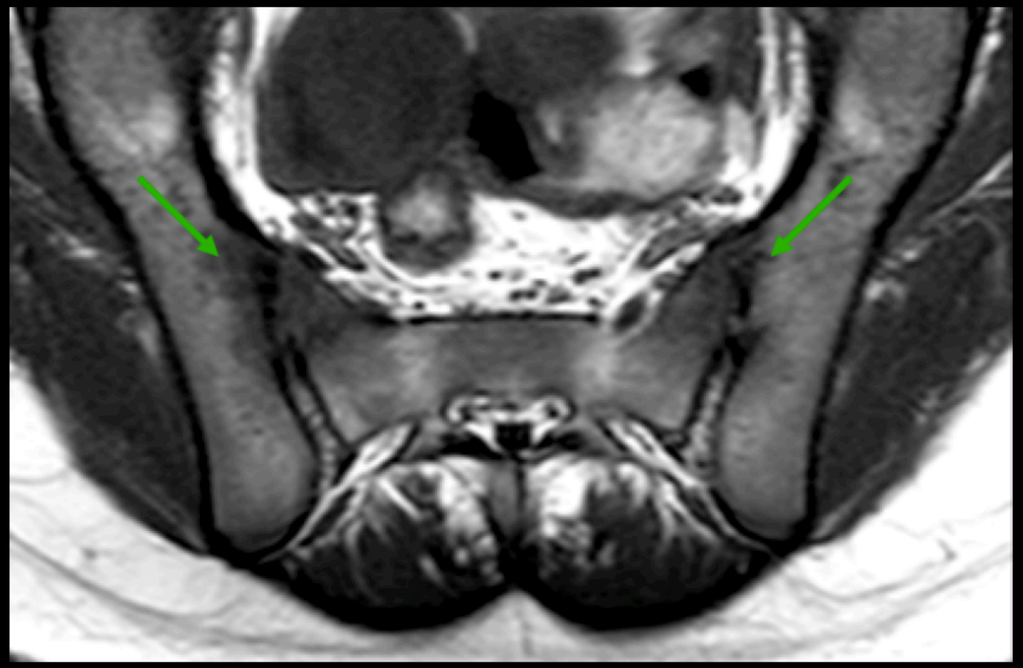

Active inflammatory sacroiliitis in a 12-year-old girl with lower back pain and juvenile idiopathic arthritis. Images demonstrate periarticular bone marrow (yellow arrow), focal erosions and bone bridges (green arrow)

SCIATIC TUBEROSITY PATHOLOGY

SCIATIC-LIKE PAIN

Hamstrings Bursitis

Prevalence: associated with repetitive stress on the hamstring tendon (sporting activities involving running, kicking or jumping)

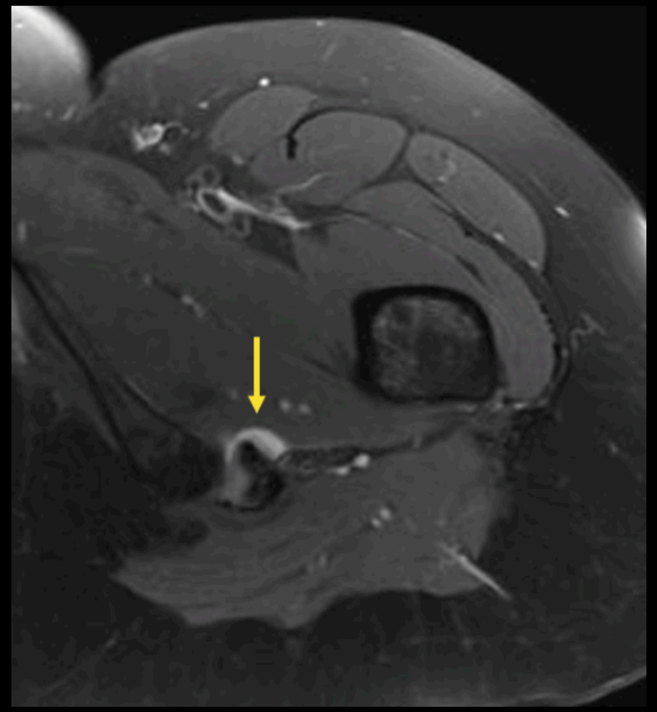

Enthesopathies and bursitis of the proximal tendon of the left hamstring (arrow) seen in axial DP SAT-weighted MRI.

Traumatic Muscle Tear

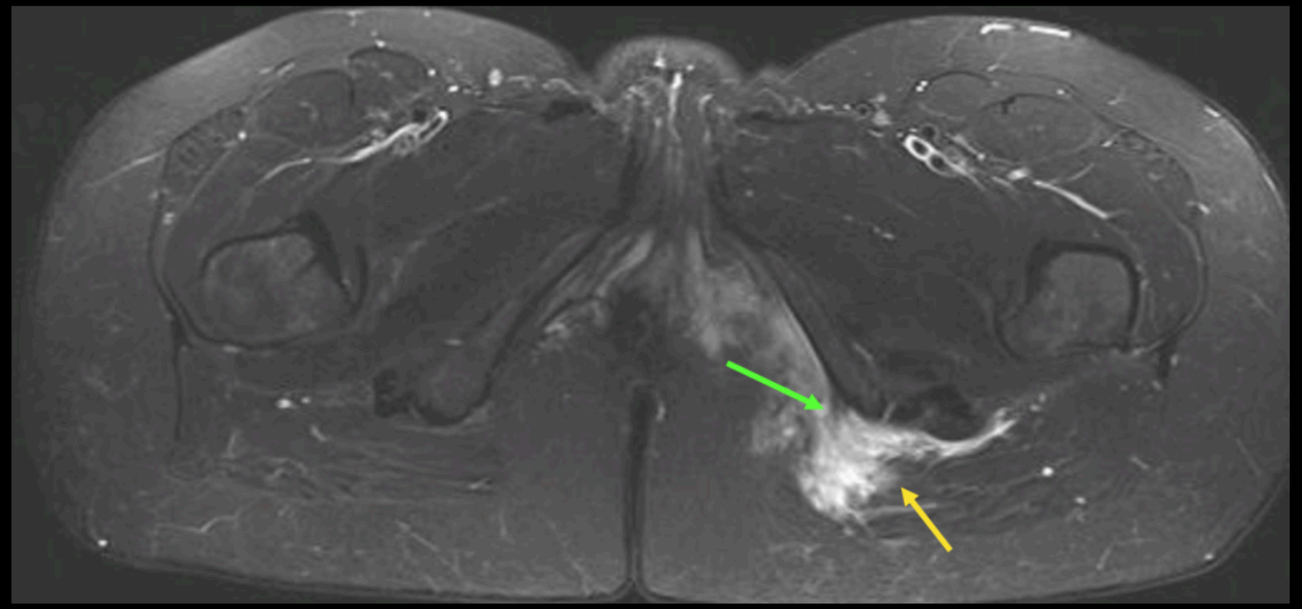

47-year-old woman after a long driving ride. We observed exuberant soft tissue edema and gluteal hematoma (yellow arrow) with partial tears of the sacrotuberous ligament (green arrow) in these edema-sensitive sequences.

Hamstring tendon pathologies can cause inflammatory changes in the perisciatic fat and secondary sciatic neuritis because of the intimate relationship of the nerve and ischial tuberosity

DIFFERENTIAL DIAGNOSES OF GLUTEAL PAIN

Ischiofemoral Impingiment

Chronic ischiofemoral impingement syndrome in a middle-aged woman.
Axial T1-weighted MRI showing reduced ischiofemoral space and liposubstitution of the left quadratus femoris, with nodular conformation, probably forming an elastofibroma (arrow)

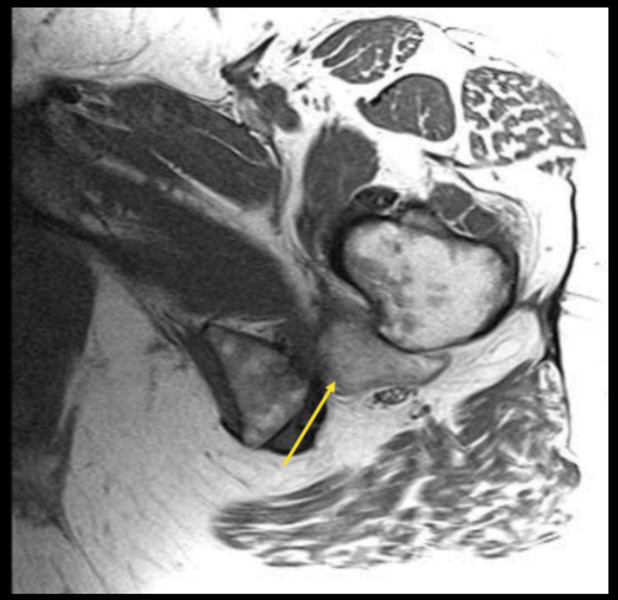

Introduction: narrowing of the ischiofemoral space leads to muscular, tendon and neural changes. The syndrome may occur acutely because of inflammation/edema or chronically because of fibrous tissue formation that traps the nerve.

Prevalence: has been increasingly recognized as an overlooked cause of hip pain. Adult female patients are most commonly affected.

Clinical Findings: distal pain lateral to the ischium; positive ischiofemoral impingement test

Imaging Findings:
- narrowing ischiofemoral space (< 1,5 - 2,0 cm)
- edema and/or hypotrophy and liposubstitution quadratus femoris muscle
- sciatic neuritis can be seen

DIFFERENTIAL DIAGNOSES OF GLUTEAL PAIN

Ischiofemoral Impingiment

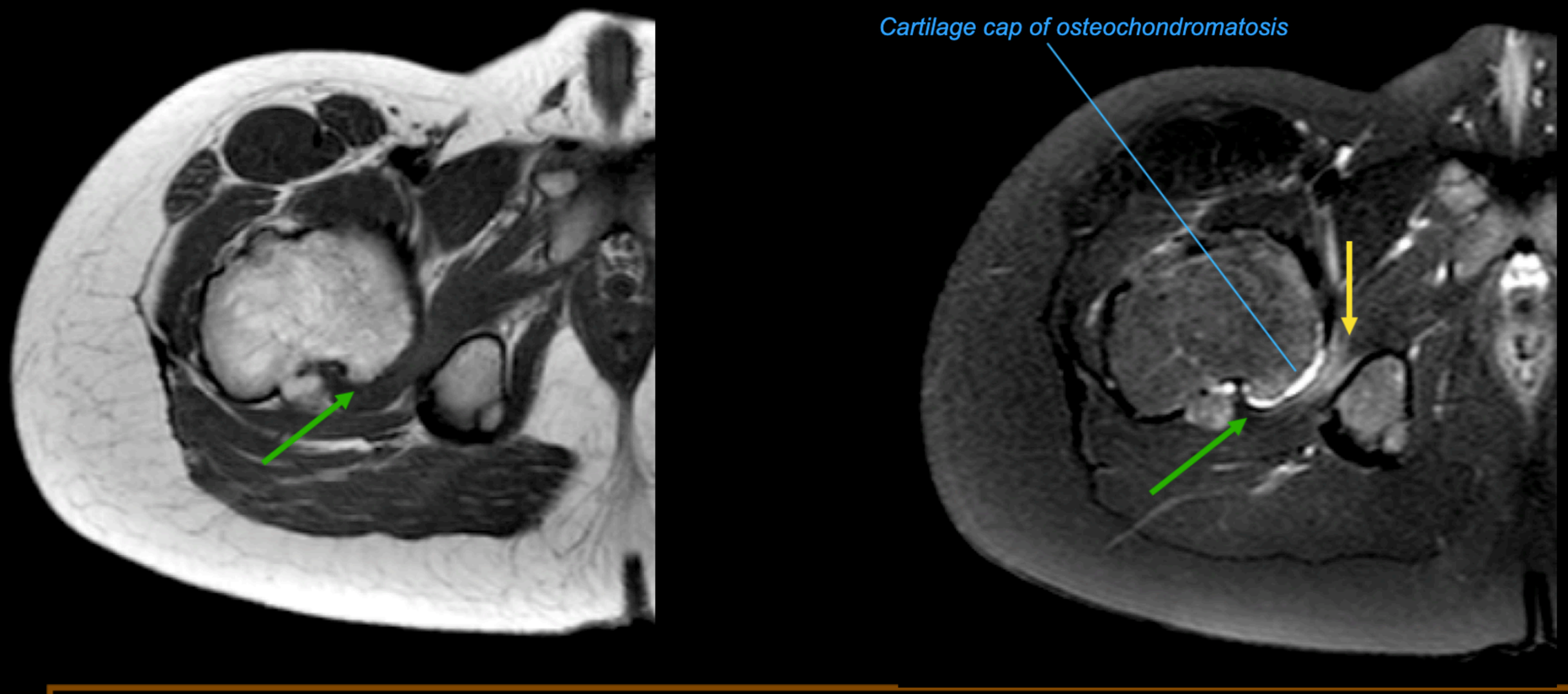

11-year-old boy with multiple osteochondromatosis presenting right gluteal pain.
Note the femoral bone exostosis reducing the ischiofemoral space (green arrow) with consequent edema of the quadratus femoris muscle belly (yellow arrow)

DIFFERENTIAL DIAGNOSES OF GLUTEAL PAIN

Ischiofemoral Impingiment

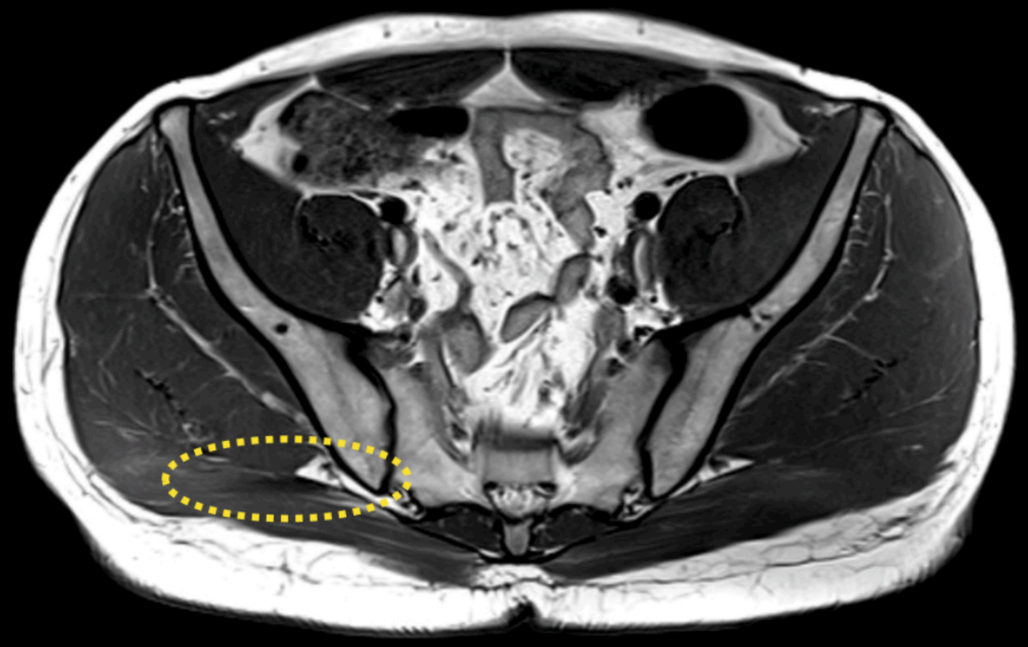

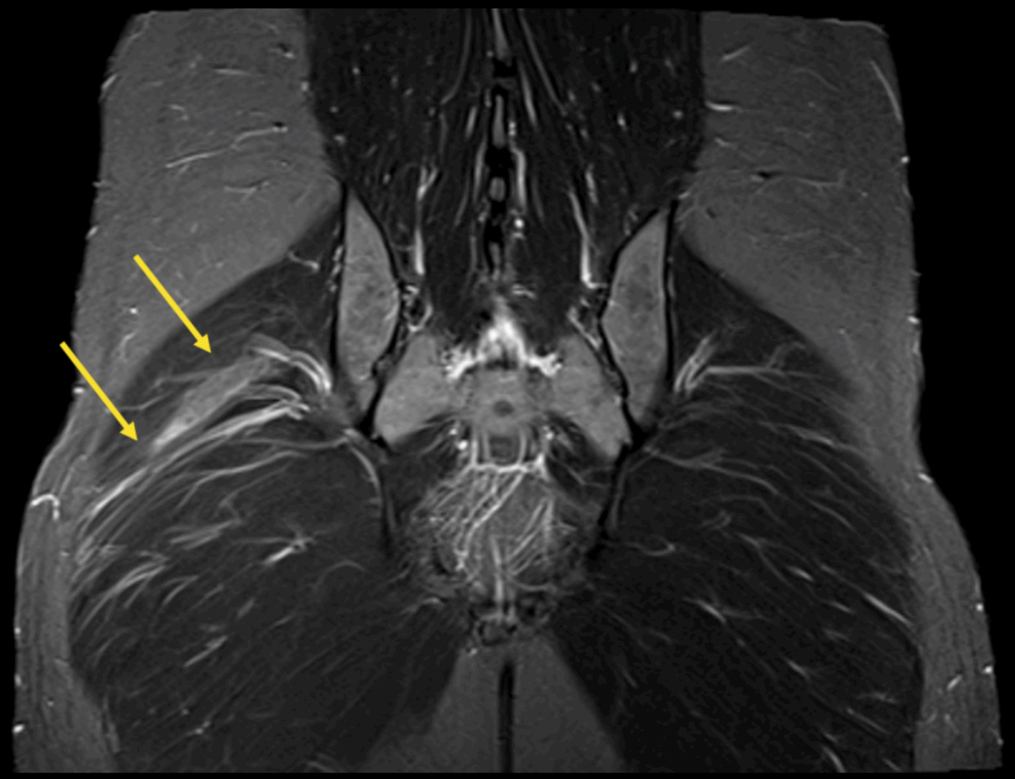

35-year-old woman with sciatica and normal lumbar spine MRI.
Observe the right gluteal muscle contracture, characterized by thickened intramuscular fibrotic cord (dashed circle) accompanied by atrophy and myofibrillar edema (arrow).

Take home message

Given the wide differential diagnosis of posterior / deep gluteal pain listed, good interaction between the radiologist and the medical team is necessary for better use of imaging protocols to narrow the diagnosis

The suggested initial evaluation is through the MRI of the Lumbosacral Spine due to the higher frequency of posterior gluteal pain of discogenic cause

Discarded the most prevalent hypothesis, other osteomuscular or neurogenic non-discogenic differential diagnoses dictated the study directed to the MRI of the Pelvis or Lumbosacral Plexography.

UNICAMP

Department of Radiology, State University of Campinas (UNICAMP), Brazil

RCC Radiologia Clínica de Campinas

José Michel Kalaf Research Institute, Campinas, Brazil

References

1. Panwar J, Mathew A, Thomas BP. Cystic lesions of peripheral nerves: Are we missing the diagnosis of the intraneural ganglion cyst? World J Radiol. 2017 May 28;9(5):230-244.
2. Saar TD, Pacquée S, Conrad DH, et al. Endometriosis Involving the Sciatic Nerve: A Case Report of Isolated Endometriosis of the Sciatic Nerve and Review of the Literature. Gynecol Minim Invasive Ther. 2018;7(2):81-85. doi:10.4103/GMIT.GMIT_24_18
3. Hernando MF, Cerezal L, Pérez-Carro L, Abascal F, Canga A. Deep gluteal syndrome: anatomy, imaging, and management of sciatic nerve entrapments in the subgluteal space. Skeletal Radiol. 2015 Jul;44(7):919-34. doi: 10.1007/s00256-015-2124-6. Epub 2015 Mar 5. PMID: 25739706
4. Park JW, Lee YK, Lee YJ, Shin S, Kang Y, Koo KH. Deep gluteal syndrome as a cause of posterior hip pain and sciatica-like pain. Bone Joint J. 2020 May;102-B(5):556-567. doi: 10.1302/0301-620X.102B5.BJJ-2019-1212.R1. PMID: 32349600
5. Martin HD, Khoury A, Schröder R, Palmer IJ. Ischiofemoral Impingement and Hamstring Syndrome as Causes of Posterior Hip Pain: Where Do We Go Next? Clin Sports Med. 2016 Jul;35(3):469-486. doi: 10.1016/j.csm.2016.02.010. Epub 2016 Apr 5. PMID: 27343397
6. Singer AD, Subhawong TK, Jose J, Tresley J, Clifford PD. Ischiofemoral impingement syndrome: a meta-analysis. Skeletal Radiol. 2015 Jun;44(6):831-7. doi: 10.1007/s00256-015-2111-y. Epub 2015 Feb 13. PMID: 25672947
7. Nucelio Lemos, Laura Cancelliere, Adrienne L K Li, Renato Moretti Marques, Gustavo L Fernandes, Corey Sermer, Kinshuk Kumar, Jose Sebastião Afonso, Manoel J B C Girão, Superior gluteal vein syndrome: an intrapelvic cause of sciatica, *Journal of Hip Preservation Surgery*, Volume 6, Issue 2, July 2019, Pages 104–108
8. Carro LP, Hernando MF, Cerezal L, Navarro IS, Fernandez AA, Castillo AO. Deep gluteal space problems: piriformis syndrome, ischiofemoral impingement and sciatic nerve release. *Muscles Ligaments Tendons J*. 2016;6(3):384-396. Published 2016 Dec 21. doi:10.11138/mltj/2016.6.3.384
9. Kizaki K, Uchida S, Shanmugaraj A, Aquino CC, Duong A, Simunovic N, Martin HD, Ayeni OR. Deep gluteal syndrome is defined as a non-discogenic sciatic nerve disorder with entrapment in the deep gluteal space: a systematic review. Knee Surg Sports Traumatol Arthrosc. 2020 Oct;28(10):3354-3364. doi: 10.1007/s00167-020-05966-x. Epub 2020 Apr 3. PMID: 32246173.
10. Lewis AM, Layzer R, Engstrom JW, Barbaro NM, Chin CT. Magnetic resonance neurography in extraspinal sciatica. Arch Neurol. 2006 Oct;63(10):1469-72
11. Kulku DG, Naderi S. Differential diagnosis of intraspinal and extraspinal non-discogenic sciatica . J Clin Neurosci 2008 Nov;15(11):1246-52.
12. Chen CK, Yeh L, Chang WN, Pan HB, Yang CF. MRI diagnosis of contracture of the gluteus maximus muscle. AJR Am J Roentgenol. 2006 Aug;187(2):W169-74.